ISSN No:-2456-2165 https://doi.org/10.38124/ijisrt/26nov625

Incidental Diagnosis of a Rare Form of Spermatic Cord Duplication Discovered During Inguinal Hernia Repair: A Case Report

M. Laroussi[1]; M. Essarghini[2]; M. Mansouri[3]; M. Tarchouli[4]

[1;2;3;4]Department of Visceral Surgery – Hassan II Hospital, Laayoune

Publication Date: 2026/11/23

Abstract: Duplication of the spermatic cord is a very rare, indeed exceptional, malformation of the internal genital tract compared with other malformations of the internal genital tract, particularly those involving the vas deferens. Variations of the vas deferens include agenesis [2], [3], [4], [7], [10], ectopic vas deferens [5], duplication [6], [8], [9], [11], and intercommunicating vas deferens [1]. The key feature of our case is that the duplication involves the vas deferens and the other neurovascular structures, which arise from two separate testes located on the same side: one testis is atrophic, while the other has normal trophicity.

How to Cite: M. Laroussi; M. Essarghini; M. Mansouri; M. Tarchouli (2026) Incidental Diagnosis of a Rare Form of Spermatic Cord Duplication Discovered During Inguinal Hernia Repair: A Case Report. *International Journal of Innovative Science and Research Technology*, 11(11), 1080-1082. https://doi.org/10.38124/ijisrt/26nov625

I. INTRODUCTION

We report a rare malformation of the internal genital tract consisting of duplication of the spermatic cord within the same hemiscrotum, discovered during inguinal hernia repair in a 38-year-old patient.

➢ *Case Presentation:*

A 38-year-old patient was admitted to our department with a right inguinal hernia. Physical examination revealed a reducible right inguinal swelling with an expansile cough impulse. There were no associated urinary or gastrointestinal symptoms.

II. RESULTS

The patient underwent a right inguinal incision. Upon opening the inguinal canal, a large indirect hernia was identified.

After opening the spermatic fascia and dissecting the indirect hernial sac, two separate structures were identified. Each contained a vas deferens and neurovascular structures (Figure 1).

After mobilization of the right hemiscrotum, the two structures were found to extend to two separate structures (Figure 2).

These were two distinct testes: one was atrophic, while the other appeared normal.

We therefore identified a duplication of the spermatic cord, with two testes on the same side, one of which was atrophic.

The procedure consisted of resection of the indirect hernial sac, followed by hernia repair using a polypropylene mesh according to the Lichtenstein technique.

Both testes were preserved on the same side, as were both spermatic cords.

III. DISCUSSION

Duplication of the vas deferens is a very rare congenital malformation [6, 8, 9, 11], with several anatomical variants. These include a supernumerary vas deferens running parallel to the normal vas deferens within the spermatic cord, or a perpendicular vas deferens that may mimic an ectopic ureter opening into the seminal tract; the latter is often associated with ipsilateral renal agenesis. From a pathophysiological perspective, this anomaly may be explained by duplication of the mesonephric duct or by differentiation of the caudal part of the mesonephric duct, which normally gives rise to the ureteric bud, into a vas deferens. This may explain cases of ipsilateral renal agenesis [19]. The anomaly is usually discovered during surgical exploration of the inguinal canal for hernia repair or orchidopexy for cryptorchidism, during investigations for congenital urinary tract abnormalities, or in adults following failed vasectomy.

ISSN No:-2456-2165 https://doi.org/10.38124/ijisrt/26nov625

Intercommunication between the vasa deferentia is probably an exceptional malformation, since, to the best of our knowledge, only one case has been reported, in a 28-year-old man undergoing investigations for infertility [1].

In our case, there were two testes and two distinct spermatic cords within the same hemiscrotum. We believe that duplication of the spermatic cord may be explained by duplication of the mesonephric duct or by agenesis of the contralateral spermatic cord and testis. Unfortunately, this possibility was neither verified nor investigated.

IV. CONCLUSION

Malformations of the internal genital tract are often diagnosed incidentally during surgery for an inguinal hernia, varicocele, cryptorchidism, or testicular ectopia.

Such findings should prompt the surgeon to explore the entire ipsilateral and contralateral urogenital tract in order to detect any previously unrecognized renal or urogenital malformations.

- *Conflicts of Interest*

The authors declare that they have no conflicts of interest.

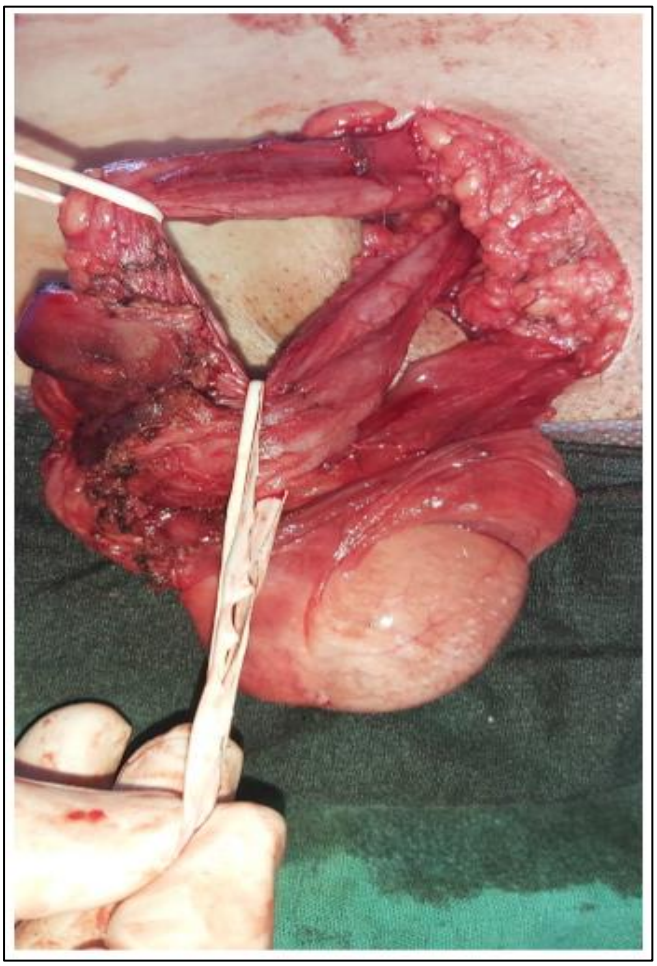

Fig1 Peroperatory Image Shows Two Separate Structures Identified. Each Contained a vas Deferens and Neurovascular Structures

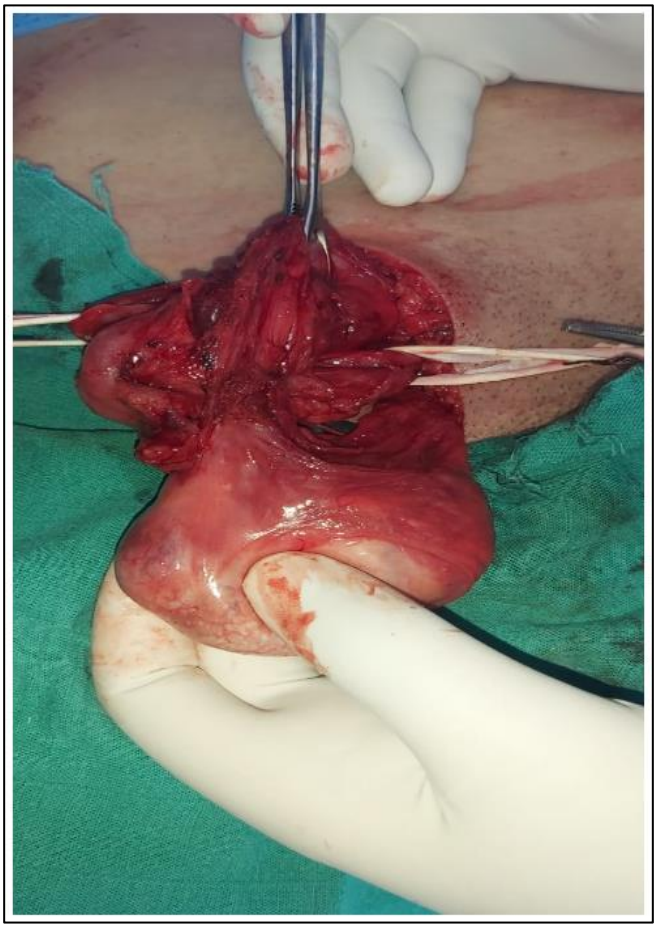

Fig 2 Peroperatory Image Shows that after Mobilization of the Right Hemiscrotum, the Two Structures were found to Extend to Two Separate Structures

REFERENCES

[1]. BEALL M.E.,WARE R.E.: Intercommunicating vas deferens. J. Urol., 1976 , 116, 126-127.

[2]. CHARNY C.W., GILLENWATER J.Y. : Congenital absence of the vas deferens. J. Urol., 1964, 93, 399-401.

[3]. DEANE A.M., MAY R.E. : Absent vas deferens in association with renal abnormalities. Brit. J. Urol. ,1982, 54, 298-299.

[4]. GIBBONS M.D., CROMIE W.J., DUCKETT J.W. : Ectopic vas deferens. J. Urol., 1978, 120, 597-604.

[5]. GOTOH T., TAKAHASSHI Y., KUMAGAI A. : Two cases of ectopic ureter opening into ejaculatory duct; double vas deferens revisited. J. Urol., 1983, 130, 550-552.

[6]. KLOTZ P.G. : Congenital absence of the vas deferens. J. Urol.,1973, 109, 662-663.

[7]. KOYANAGI T.,TSUJI I., KUDO T. : Double vas deferens associated with ipsilateral renal agenesis, simulating ectopic ureter. J.Urol.,1972, 108, 631-634.

[8]. MATHÉ C.P., DUNN G. : Double vas deferens associated with solitary kidney:case report. J.Urol., 1948, 59, 461-466.

[9]. RUBIN S.O. : Congenital absence of the vas deferens.Scand. J. Urol Nephrol., 1975, 9, 94-99.

ISSN No:-2456-2165 https://doi.org/10.38124/ijisrt/26nov625

[10]. SCHLEGEL P.N., SHIN D., GOLDSTEIN M. : Urogenital anomalies in men with congenital absence of the vas deferens. J. Urol., 1996, 155, 1644-1648. .
[11]. TOLETE-VELCEK F., LEDDOMADO E., HANSBROUGH H. : Alleged resection of the vas deferens : medicolegal implications. J.Pediatr.Surg., 1988, 23, 21-23.