

When Hydatidosis Mimics Empyema: Case Report of a Ruptured Intrapleural Pulmonary CYST

Mohamed Karmil¹; Hamza Oualhadj²; Faycal Idem¹; Awatif El Hakkouni¹

¹. Laboratory of Parasitology, University hospital Mohammed VI, Marrakech

². Laboratory of Immunology, University hospital Mohammed VI, Marrakech

Corresponding Author

Mohamed Karmil

Address : 77 DB Aarjan, 40000, Marrakech, Morocco

Publication Date: 2025/05/24

Abstract: Pulmonary hydatid disease, caused by the larval stage of *Echinococcus granulosus*, is an uncommon condition, even in endemic areas. Humans become accidental intermediate hosts by ingesting food or soil contaminated with eggs excreted by canines, the definitive hosts. In primary echinococcosis, larval cysts can develop in almost any organ, most commonly the liver, followed by the lungs.

Pulmonary hydatid cysts often remain asymptomatic until they rupture, at which point patients may present with symptoms such as productive cough, hemoptysis, fever, or pleural effusion. While parenchymal cysts are rare, extra parenchymal intrapleural hydatid cysts are even more unusual.

We report the case of a 42-year-old male who developed a massive unilateral pleural effusion following the rupture of an intrapleural hydatid cyst. This case underscores a rare but important differential diagnosis for pleural effusion.

The objective of this report is to highlight this unusual presentation of hydatidosis, explore its potential complications, and discuss the available treatment options, including surgical intervention and medical management.

How to Cite: Mohamed Karmil; Hamza Oualhadj; Faycal Idem; Awatif El Hakkouni (2025) When Hydatidosis Mimics Empyema: Case Report of a Ruptured Intrapleural Pulmonary CYST. *International Journal of Innovative Science and Research Technology*, 10(5), 1303-1306. <https://doi.org/10.38124/IJISRT/25may902>

I. INTRODUCTION

Hydatidosis is an anthroponosis endemic to Morocco and constitutes a significant public health concern [1]. In primary echinococcosis, larval cysts can develop in nearly any organ. Among adults, the lungs are the second most commonly affected organ after the liver [2]. Although rare, intrapleural rupture of pulmonary hydatid cysts is a serious complication that poses considerable diagnostic and therapeutic challenges. We report the case of a 42-year-old male who developed a massive unilateral pleural effusion following the rupture of an intrapleural hydatid cyst. This case underscores a rare but important differential diagnosis for pleural effusion.

II. CASE REPORT

A 23-year-old male from a rural area was admitted to the emergency department with acute severe dyspnea, following a 4-month history of intermittent fever and non-productive cough. He reported no history of tuberculosis exposure, chronic respiratory diseases, diabetes mellitus, or hypertension.

On general physical examination, findings were within normal limits. However, respiratory system evaluation revealed decreased left-sided chest movement. Percussion over the left hemithorax produced a dull note, and auscultation showed almost absent vesicular breath sounds along with reduced vocal resonance on the same side.

Laboratory investigations demonstrated:

- Normal complete blood count and hemoglobin
- Mild eosinophilia (800 cells/mm³)
- Elevated inflammatory markers: ESR and C-reactive protein (35 mg/L)

- Normal renal and liver function tests

A chest X-ray showed a complete homogeneous opacity of the left hemithorax, suggestive of massive pleural effusion [Figure 1].

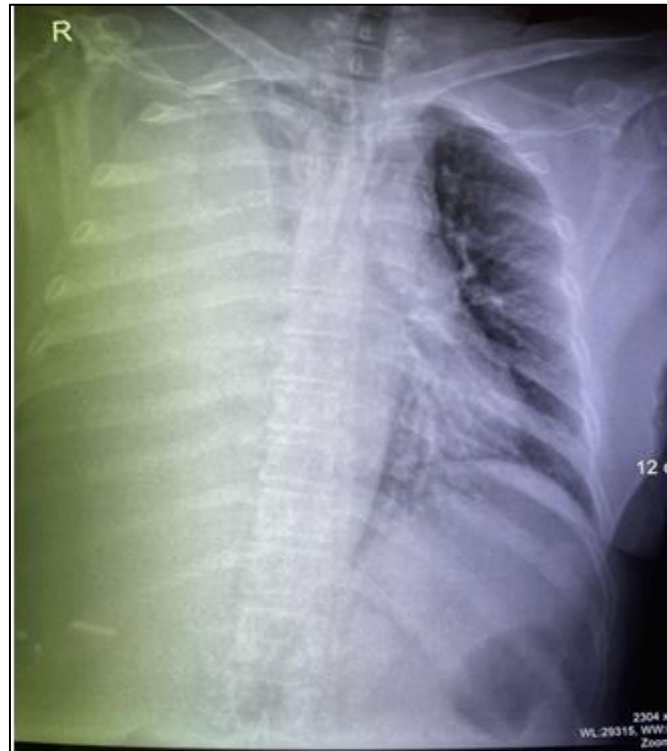


Fig 1: Chest X-Ray Demonstrating a Homogeneous Opacity of the left Hemithorax, Consistent with Massive Pleural Effusion and Significant Fluid Accumulation.

The patient underwent thoracic drainage, which yielded turbid pleural fluid containing detached membranes. Parasitological examination of the fluid revealed free hooklets of *Echinococcus granulosus* on direct microscopy, confirming the diagnosis of pulmonary hydatidosis. [Figure 2].

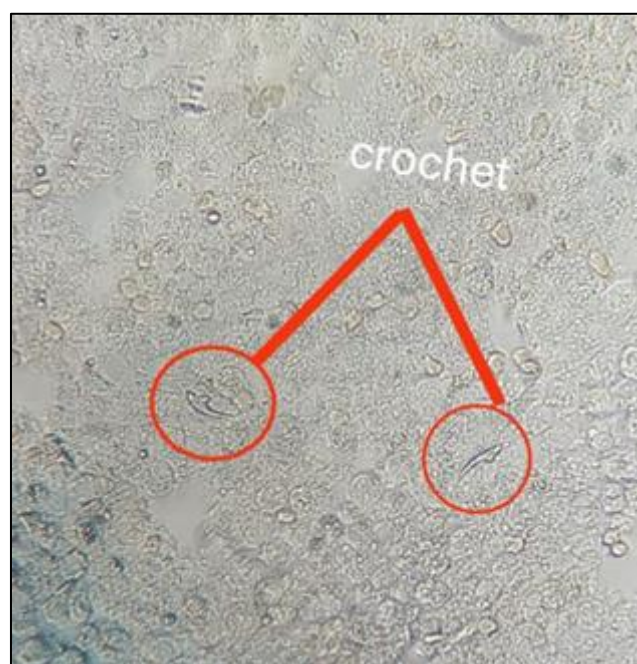


Fig 2 : Free Hooklets of Echinococcus Granulosus

A thoracic and abdominal computed tomography (CT) scan, performed on day 3 of drainage, confirmed the presence of a hydatid cyst in the left lower lobe along with pericystic parenchymal condensation. Echinococcal serology, performed using Enzyme-Linked Immunosorbent Assay (ELISA), was strongly positive.

The patient subsequently underwent decortication-pleurectomy along with left lower lobectomy and enucleation of the hydatid cyst. The residual cyst cavity was irrigated with hypertonic saline, cleaned with hydrogen peroxide, and then closed.

Postoperatively, the patient received albendazole 500 mg twice daily for 8 weeks. He was discharged in a stable condition, and follow-up at 3 months showed complete resolution of symptoms.

III. DISCUSSION

Hydatid disease is an endemic parasitic infection in Morocco, primarily due to the close contact between humans and domestic animals, especially sheep and dogs. It is most commonly caused by the larval stage of *Echinococcus granulosus*. Humans serve as accidental intermediate hosts, acquiring the infection through ingestion of food or soil contaminated with eggs excreted by canines, the definitive hosts.

The liver is the most frequently affected organ, involved in approximately 75% of cases, followed by the lungs in 15%, and other anatomical locations in 10% [1]. Within the lungs, cysts are more commonly found in the lower lobes, with a distribution of 50% in the right lung, 40% in the left lung, and 10% bilateral involvement [2].

Uncomplicated pulmonary hydatid cysts (including unruptured ones) are often asymptomatic and diagnosed incidentally. Symptoms typically arise due to cyst enlargement or, more commonly, as a result of complications such as rupture [4].

Rupture into the pleural cavity is a rare but severe complication that can present with a wide spectrum of clinical and radiological features, including pneumothorax, hydropneumothorax, empyema, pleural thickening, abscess formation, and tension pneumothorax [5]. These manifestations can mimic malignancies, complicating the diagnostic process. Rupture may occur spontaneously, traumatically, or iatrogenically [8, 9]. Clinical symptoms such as chest pain, cough, cyanosis, fever, and dyspnea arise due to the discharge of cyst contents into the pleural space and collapse of the germinative membrane, leading to compression of the adjacent lung parenchyma [6].

Diagnosis is typically confirmed by microscopic or histopathological examination of hydatid fluid obtained surgically. However, serology plays a key role in preoperative diagnosis, especially when used in combination with imaging techniques such as CT scans. On

CT, signs such as the inverse crescent sign and signet ring sign are characteristic of pulmonary hydatid cysts [7]. In ruptured or complicated cases, pathognomonic CT findings include detached or collapsed endocyst membranes, collapsed daughter cysts, and intact daughter cysts [6].

Surgical management is the treatment of choice for ruptured or large cysts, aiming for complete excision while preserving as much functional lung parenchyma as possible. Adjunctive therapy with albendazole is recommended, especially in cases of cyst rupture or in patients at high surgical risk. Although the precise role of anthelmintic drugs remains debated, albendazole has been shown to reduce cyst viability, making it a useful perioperative and secondary treatment option. Recommended doses are typically 10 mg/kg daily for 3–4 weeks [10].

Serological follow-up is essential in monitoring treatment response. Persistent high antibody levels, or a rebound in titers after initial negativation, may suggest treatment failure, recurrence, or secondary echinococcosis [11].

IV. CONCLUSION

Pulmonary hydatid disease, while relatively uncommon, should remain a differential diagnosis in patients presenting with pleural effusion in endemic regions. Rupture of a pulmonary hydatid cyst into the pleural space is a rare but serious complication that can mimic other thoracic pathologies, leading to diagnostic delays. Early recognition, supported by imaging and serology, is critical for prompt and appropriate management. Surgical intervention remains the cornerstone of treatment, complemented by antiparasitic therapy to reduce the risk of recurrence. This case highlights the importance of considering hydatidosis in atypical presentations and underscores the need for continued public health measures to control echinococcal transmission in endemic areas.

DISCLOSURE

The authors declare no conflict of interest

REFERENCES

- [1]. Gursoy S, Ucvet A, Tozum H, et al. Primary intrathoracic extrapulmonary hydatid cysts: analysis of 14 patients with a rare clinical entity. *Tex Heart Inst J*. 2009 ;36:230–233.
- [2]. Akbulut S, Yavuz R, Sogutcu N, Kaya B, Hatipoglu S, et al. Hydatid cyst of the pancreas: Report of an undiagnosed case of pancreatic hydatid cyst and brief literature review. *World J Gastrointest Surg* 2014 ;6(10):190–200.
- [3]. Erkoç MF, Öztoprak B, Alkan S, Okur A. A rare cause of pleural effusion : ruptured primary pleural hydatid cyst. *BMJ Case Rep* 2014 ;2014.

- [4]. B. Srinivasan, P.N. Mohite, S.K. Thingnam
Extrapulmonary intrapleural hydatid cysts-rare variant of uncommon disease. *Indian J Thorac Cardiovasc Surg*, 26 (2010).
- [5]. A.T. Turgut, T. Altinok, S. Topcu, U. Kosar Local complications of hydatid disease involving the thoracic cavity: imaging findings *Eur J Radio*, 70 (1) (2009), pp. 49-56.
- [6]. Marghli A, Ayadi-Kaddour A, Ouerghi S, Boudaya MS, Zairi S, Smati B, et al. Primary heterotopic pleural hydatid cyst presenting as a pneumothorax. *Rev Mal Respir* 2011 ;28(3):344–7.
- [7]. Gursoy S, Ucvet A, Tozum H, Erbaycu AE, Kul C, Basok O. Primary intrathoracic extrapulmonary hydatid cysts: analysis of 14 patients with a rare clinical entity. *Tex Heart Inst J* 2009;36.
- [8]. Tewari M, Kumar V, Shukla HS. Primary pleural hydatid cyst. *Indian J Surg* 2009;71(2):106.
- [9]. Sebit S, Tunc H, Gorur R, et al. the evaluation of 13 patients with intrathoracic extra pulmonary hydatidosis. *J Int Med Res*. 2005 ;33:215–221. doi: 10.1177/147323000503300209.
- [10]. A. Giorgio, L. Taranyino, G. Francica, N. Mariniello, E. Soscia, G. Pierri .Unilocular hydatid liver cysts: treatment with US-guided, double percutaneous aspiration and alcohol injection. *Radiology*, 184 (3) (1992), pp. 705-710.
- [11]. P.J. Ochieng'-Mitula, M.D. Burt. The effects of ivermectin on the hydatid cyst of *echinococcus granulosus* after direct injection at laparotomy. *J Parasitol*, 82 (1) (1996), pp. 155-157