

CBCT Analysis of Radix Entomolaris: Anatomical and Endodontic Implication

Dr. Sameeksha Bhardwaj¹; Dr. Vinay Mohan²; Dr. Anuj Gaur³; Dr. Niharika⁴

Department of Oral Medicine and Radiology
K.D Dental College and Hospital, Mathura, India

Abstract:- This paper aims to provide examples of mandibular first molars that have an extra distolingual root and discuss how to manage them with the right tools and methods. Mandibular molars occasionally exhibit radix entomolaris, a variant in which the tooth has an additional root fixed to its lingual aspect. If this extra root is misdiagnosed or treated improperly, it could make endodontic management of the tooth more difficult. Thus, Understanding the variances in tooth/canal architecture and distinguishing traits is essential since it can help with canal location, negotiation, and management. Mandibular molars with this root shape have a different prognosis depending on the precise diagnosis and appropriate use of clinical endodontic competence.

Keywords:- Mandibular Molars, Radix Entomolaris.

I. INTRODUCTION

Germs are well established in the unique anatomic location of the root canal system, making them immune to host defences and systemically delivered medications. Endodontic treatment that lowers the bacterial burden primarily consists of intracanal medicine and chemo mechanical preparation. Therefore, a successful outcome of root canal therapy can be attributed to knowledge and comprehension of the existence of atypical root canal morphology.^[1]

The mandibular first molar is known to exhibit a variety of anatomical variants. The most common and well-known variation in this group is the third root being present in the permanent first molar, which was initially reported by Carabelli. Radix entomolaris (RE) is the name of an extra root that is lingually present.^[2]

According to Bolk, it is known as radix paramolaris (RP) when it occurs on the mesiobuccal side. Compared to RE, Radix Paramolaris happens less frequently. The RE can range in size from a small conical extension to a mature root.^[3]

RE was categorised into four categories (A, B, C, and AC) by Carlsen and Alexandersen based on where the cervical portion of the RE was located. The cervical portion of the RE that is placed farther away and has two normal and one normal distal root component, respectively, is referred to as Type A or Type B.^[4]

The mesially placed cervical section is referred to as Type C, while the middle placement between the distal and mesial root components is referred to as Type AC. It is possible to distinguish between separate and nonseparate RE thanks to this classification.

According to De Moor et al., the curvature of the variant can determine one of three forms of RE.

- Type I denotes a straight root or canal
- Type II denotes an entrance that is initially curled and then continues as a straight root/canal.
- Type III describes a root canal with two curves: one in the coronal third and the other starting in the middle and extending to the apical third.^[5]

This article describes the morphologic variation of radix entomolaris in Cone beam computed tomography.

II. CASE REPORT

A 25-year-old female patient reported to the Department of Oral Medicine and Radiology, K.D. Dental College and Hospital, with the chief complaint of pain in right mandibular posterior tooth region of lower jaw for 30 days. Pain was continuous in nature and aggravated on chewing food and consumption of cold beverages and relieved on taking medication.

Clinical examination revealed that 46 were carious and was tender on percussion. Radiographs were taken and showed radiolucency involving pulp and widening of periodontal ligament with respect to 46 indicating caries. Medical history was non-contributing.

A Cone Beam CT was performed on CS 9600 to evaluate the status and endodontic requirement for tooth number 46. Images were acquired around the patients head with slice thickness of 75 Micron (0.075 mm). The acquired data was reconstructed into MPR and panoramic projections to depict the tooth no 46 for needful management.

In 3D Section 3 Roots seen w.r.t 46 i.e., Mesial, Distobuccal and one root seen lingually on distal side of tooth suggestive of Radix Entomolaris.

In Axial Section, 4 Orifices pinpoint hypodensity are seen w.r.t 46 indicating 4 canals i.e., Mesiobuccal, Mesiolingual, Distobuccal, Distolingual.

A Well-defined hypodensity is seen w.r.t 46 involving distobuccal and mesial root suggestive of periapical lesion.

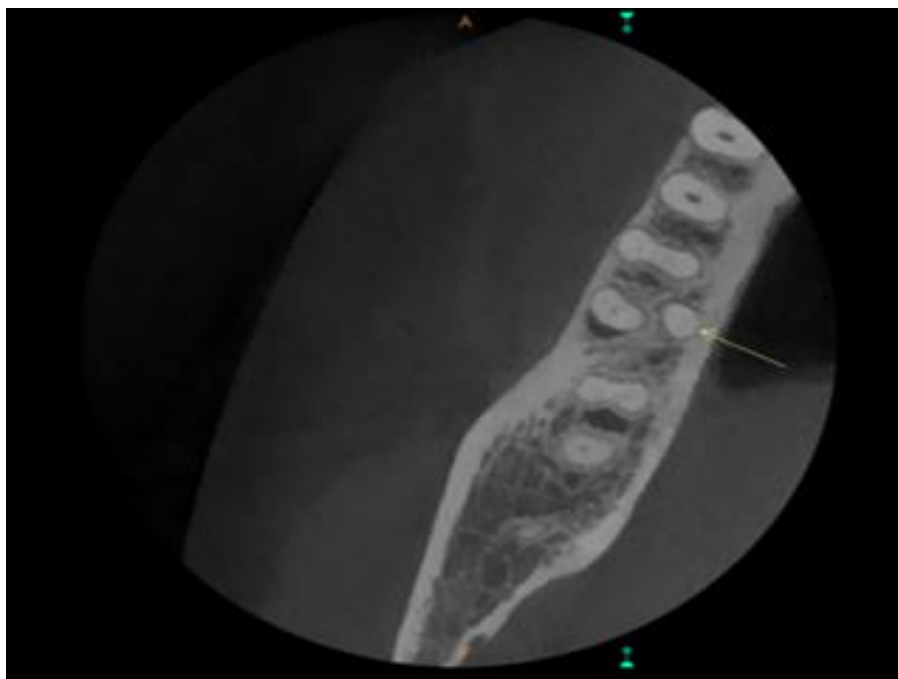


Fig 1 In Axial Section Showing one Extra Root

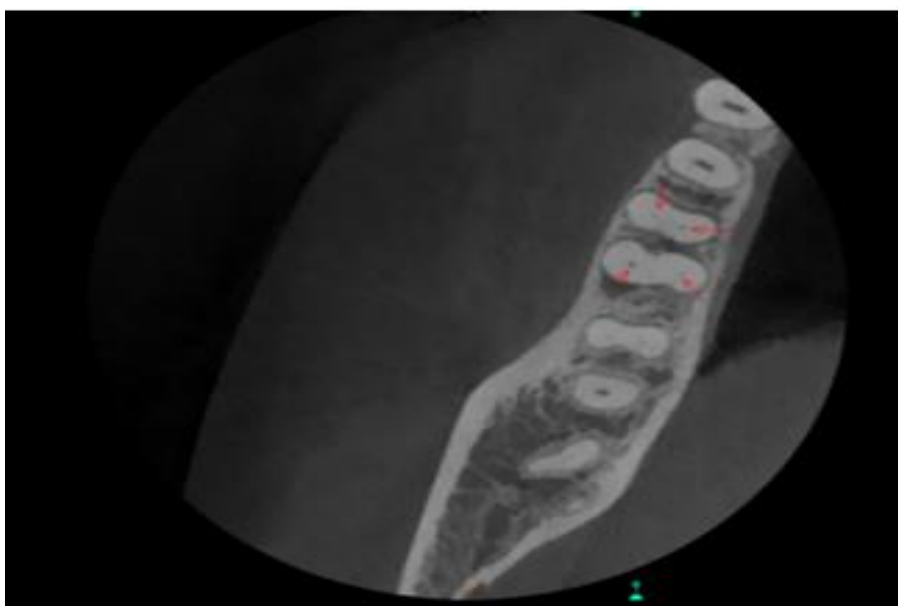


Fig 2 In Axial Section Showing 4 Orifices.

III. DISCUSSION

Anatomical differences are a recognised trait of mandibular permanent molars. While the majority of mandibular molars have two roots—a mesial and a distal root—it is infrequently possible to find an additional distolingual root. Some writers view a radix entomolaris as a hereditary characteristic as opposed to a defect in development.

The fact that the feature was equally prevalent in pure Eskimo and mixed-race Eskimo/Caucasian individuals suggests that these "three-rooted molar" qualities had a high

degree of genetic penetration. While it has a very low occurrence (<5%) in other people, such as the Indian population, it may be a normal morphological variance in ethnic groups of mongoloid descent (>30%).^[6]

RE roots can range in length from a tiny conical extension to a full-length root and are typically present distolingually.

The root can be bilateral or unilateral in its extension, and although though it is short and conical in shape, it may still include pulpal tissue.^[7]

RE can be divided into four categories based on where its cervical portion is located.

- Type A: The distal root complex, which contains two cone-shaped macrostructures, is lingually to the RE.
- Type B: The distal root complex, which comprises a single cone-shaped macrostructure, lies lingually next to the RE.
- Type C: The mesial root complex and the RE are lingually situated.
- Type AC: Between the mesial and distal root complexes, lingually, is where the RE is situated.^[8]

Each type has a subclassification to allow for the identification of separate or non separate RE.

It is necessary for the practitioner to be extremely careful while diagnosing and treating lower molar teeth because such an aberration is uncommon. An additional cusp (tuberculum paramolare), a more pronounced occlusodistal or distolingual lobe, or a more bulbous crown contour can all be seen during a clinical examination of the teeth. An extra root may be present if these are paired with a cervical protrusion or convexity. In this regard, clinical exam aids like dental microscopes, intraoral cameras, and magnifying loupes may be helpful. About 90% of the time, a third root should be clearly visible on radiography.^[9]

When a distal root contour or the root canal are obscured or difficult to see, a thorough examination of the radiograph may occasionally show the existence of a "hidden" RE. Its small size could, however, occasionally cause it to be overlooked. A second exposure of the affected tooth from three different horizontal projections—the buccal-to-lingual projection standard, 20 degrees from the mesial, and 20 degrees from the distal—provides all the fundamental details about the tooth's architecture.^[10]

Cone-beam computed tomography has proven to be an effective diagnostic technique for intricate root canal anatomy. The location and direction of the curvature were identified using the CBCT pictures in the initial case report. This proved to be very helpful in cleaning, contouring, and obturating the root's type 3 curvature.

After a diagnosis is made and an access cavity needs to be built, establishing a "straight line access" requires careful planning.

To detect and access the root canal, the traditional triangle access cavity must be modified to a trapezoidal form due to the distolingually positioned opening of the RE. Finding additional orifices may be made easier by the laws of orifice location. But caution must be used to prevent gouging or too removing dentin as this could compromise the structure of the tooth.^[11]

The research indicates that most radix entomolaris have curves. An extra curve may occasionally appear, beginning at the apical third or the middle of the root.

Pre curved files are therefore the preferred method for creating a smooth glide path to the apical segment, while Nickel-Titanium rotary files are used for cleaning and shaping. Sufficient coronal expansion prevents obstructions in the coronal section of the canals and facilitates the endodontic file's smooth passage.

Additionally, it would enable larger amounts of root canal irrigants to reach the apical region. To determine the root's length and curvature, radiographs of the tooth obtained at various angulations and CBCT scans should be carefully examined.

Electronic apex locators can be used in these situations to confirm the root length. However, even with the most advanced equipment, endodontic errors can still happen, thus caution must be used when manipulating and cleaning these curved canals.^[12]

REFERENCES

- [1]. Siqueira JF Jr., Rôças IN. Clinical implications and microbiology of bacterial persistence after treatment procedures. *J Endod* 2008;34:1291-301.e3.
- [2]. Carabelli G. *Systematisches Handbuch der Zahnheilkunde*. 2nd ed. Vienna: Braumuller und Seidel; 1844. p. 114.
- [3]. Bolk L. Welcher Gebi_reihe gehören die Molaren an? *Z Morphol Anthropol* 1914;17:83-116.
- [4]. Carlsen O, Alexandersen V. Radix entomolaris: Identification and morphology. *Scand J Dent Res* 1990;98:363-73.
- [5]. De Moor RJ, Deroose CA, Calberson FL. The radix entomolaris in mandibular first molars: An endodontic challenge. *Int Endod J* 2004;37:789-99
- [6]. M. E. Curzon and J. A. Curzon, "Three-rooted mandibular molars in the Keewatin Eskimo," *Journal of the Canadian Dental Association*, vol. 37, no. 2, pp. 71-72, 1971.
- [7]. W. Somogyi-Csizmazia and A. J. Simons, "Three-rooted mandibular first permanent molars in Alberta Indian children," *Journal of the Canadian Dental Association*, vol. 37, no. 3, pp. 105-106, 1971.
- [8]. O. Carlsen and V. Alexandersen, "Radix entomolaris: identification and morphology," *Scandinavian Journal of Dental Research*, vol. 98, no. 5, pp. 363-373, 1990.
- [9]. R. T. Walker and L. E. Quackenbush, "Three-rooted lower first permanent molars in Hong Kong Chinese," *British Dental Journal*, vol. 159, no. 9, pp. 298-299, 1985.
- [10]. R. M. F. Klein, S. A. Blake, B. R. Nattress, and P. N. Hirschmann, "Evaluation of X-ray beam angulation for successful twin canal identification in mandibular incisors," *International Endodontic Journal*, vol. 30, no. 1, pp. 58-63, 1997.

- [11]. J. I. Ingle, G. S. Heithersay, and G. R. Hatwell, Endodontic Diagnostic Procedures, BC Decker, London, UK, 2002.
- [12]. F. L. Calberson, R. J. De Moor, and C. A. Deroose, “The radix entomolaris and paramolaris: clinical approach in endodontics,” *Journal of Endodontics*, vol. 33, no. 1, pp. 58–63, 2007.