

Prosthetic Rehabilitation of Compromised Ridges: Maxillary Flabby Ridge and Severely Resorbed Mandibular Ridge – A Case Report

Dr. Riddhi Sharma¹, Dr. Naveen Oberoi², Dr. Ravpreet Singh³

¹Post Graduate Student, Department of Prosthodontics and crown & Bridge, Baba Jaswant Singh Dental College and Hospital, Ludhiana

²Professor and Head, Department of Prosthodontics and crown & Bridge, Baba Jaswant Singh Dental College and Hospital, Ludhiana

³Associate Professor, Department of Prosthodontics and crown & Bridge, Baba Jaswant Singh Dental College and Hospital, Ludhiana

Abstract:- Fabrication of any dental prosthesis over a compromised residual alveolar ridge is really a challenge for prosthodontists. Fibrous or flabby ridge and highly resorbed residual alveolar ridge are two clinical situations that require special considerations during construction of any prosthesis. Mobile soft tissue and flattened alveolar ridge significantly compromise denture stability and support. There are different treatment modalities to manage these clinical conditions like surgical excision of soft tissue, ridge augmentation, modification in impression technique, etc. Prosthodontic management of a patient with compromised residual alveolar ridges needs special consideration. Selection of treatment modality depends on patient's general health, clinical condition of residual alveolar ridges, financial capacity and skill of the clinician. A modification from conventional impression procedure was used to record maxillary flabby anterior ridge and neutral zone concept was applied for teeth arrangement to improve denture stability in atrophied lower alveolar ridge. This case report is about an old completely edentulous male patient who reported with a complaint of difficulty in chewing with his present denture.

Keywords:- *Compromised Ridges, Fibrous Tissue, Window Technique, Resorbed Ridge, Neutral Zone.*

I. INTRODUCTION

Flabby ridge is a mobile or highly resilient alveolar ridge which results from replacement of bone by fibrous tissue ^[1]. Hypermobile ridge tissue is commonly seen in the anterior portion of the edentulous maxilla or overlying an

atrophic knife edge mandibular ridge. This condition occurs due to excessive load on the residual alveolar ridge caused by unstable occlusal forces from an ill-fitting denture or from the remaining natural teeth ^[2]. Resorption of residual alveolar ridge is chronic, progressive, irreversible pathophysiological process, probably of multifactorial origin ^[3]. Conventional approach to fabricate a complete denture prosthesis is quite challenging because denture stability, retention and support are significantly jeopardized in these conditions.

Management of flabby ridge can be – (1) surgical excision of fibrous tissue, (2) non-surgical (recording the hypermobile tissue without pressure) (3) injection of sclerosing solution. An atrophied mandibular ridge can be surgically corrected by bone grafting and prosthetically managed by implant supported overdenture. But surgical treatment is a complex and time consuming procedure and in severely debilitated patients non-invasive, conservative approach is many times preferable.

II. CASE REPORT

A 65 year old male patient reported to the department of prosthodontics and crown and bridge, Baba Jaswant Singh Dental College, Hospital and Research Institute, Ludhiana and complained of difficulty in chewing with his present denture. The patient had a history of wearing maxillary and mandibular complete dentures for 7 years.

On examination, flabby tissue in the maxillary anterior region was found. The tissue was blanched on pressure application. Mandibular ridge was highly resorbed and flattened (Fig. 1).

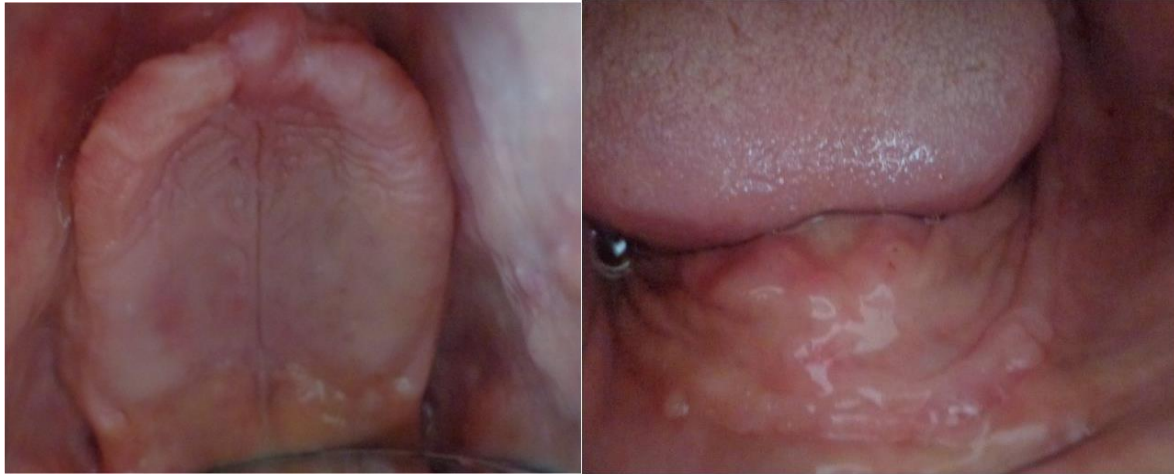

Fig 1:- Maxillary flabby ridge and resorbed mandibular alveolar ridge

➤ *Treatment Planning:*

The patient was 65 years old with a medical history of diabetes and hypertension. He did not agree to undergo any surgical procedure and refused to take any sclerosing solution. So, fabrication of a new complete denture was planned for this patient. Recording of flabby tissue in undisplaced condition using window technique and neutral zone concept for arrangement of mandibular teeth were decided to construct the complete denture prosthesis.

➤ *Treatment Procedure*

- Maxillary arch - The preliminary impression (Fig. 2) was made using irreversible hydrocolloid (Algitex ,DPI , Mumbai, India) to minimize distortion of the displaceable flabby tissue using perforated edentulous stock tray and the primary cast was poured using dental plaster (type -2 dental plaster , Neelkanth Healthcare, India). The flabby area was marked on the cast with an indelible pencil. A double thickness modelling wax spacer (Modelling wax, MDM Y-Dent, Delhi, India) was adapted over the marked

flabby tissue area and a single thickness wax spacer was placed over the remaining non-displaceable areas of the cast. A closely fitting special tray was fabricated using pink coloured autopolymerising resin (DPI RR Cold cure, The Bombay Burmah Trading Corporation, Mumbai, India). The extension of the tray was checked in the mouth and necessary adjustment was done. A window was prepared in special tray corresponding to the area of flabby tissue. Border molding was done in conventional way using green stick impression compound (DPI Pinnacle Tracing Sticks, The Bombay Burmah Trading Corporation, Mumbai, India). The wax spacer was removed and impression was made using zinc oxide eugenol paste (Impression paste, Coltene, Switzerland). Any excess paste in the flabby area was removed and an impression of the displaceable mucosa was recorded by light body polyvinyl siloxane material over the fibrous ridge area. The material was allowed to set and removed as a single impression (Fig. 3). The master cast was made with type 3 dental stone (Kalstone ,Kalabhai Karson Pvt Ltd., Mumbai, India).

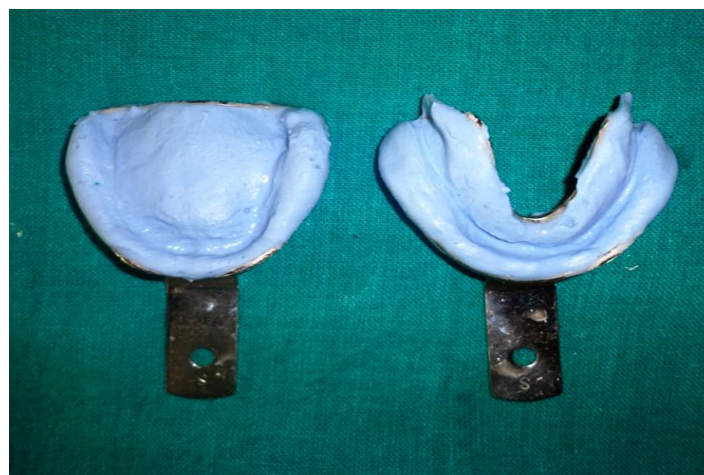

Fig 2:- Preliminary Impression of edentulous arches




Fig 3:- Final impression of maxillary arch (Window technique)

- Mandibular arch - Primary impression was made in stock tray using irreversible hydrocolloid (Algitex ,DPI , Mumbai, India) and the cast was poured using type 2 dental plaster. A special tray was fabricated from the working cast and border moulding was done in conventional manner. Tissue conditioner (Visco- gel, Dentsply De Trey, Germany) was used as final impression material to record the highly resorbed mandibular ridge by doing functional movements of orofacial musculature (functional impression technique). Master cast was made using type 3 dental stone.
- One record base for maxillary ridge and two record bases for mandibular ridge were made in self cure acrylic resin. The record bases were inserted into the mouth to check stability. The wax occlusal rim was fabricated for upper arch. The maxillary occlusal rim was inserted into the mouth and parallelism was checked using fox occlusal plane. Now, four vertical stops (two in molar region and two in canine region) made of self-cure acrylic resin were fabricated in the lower base plate and a tentative vertical jaw relation (VDO) was then recorded (Fig. 4). These resin stops acted as retentive tag of admix material and maintained the vertical height during neutral zone recording.

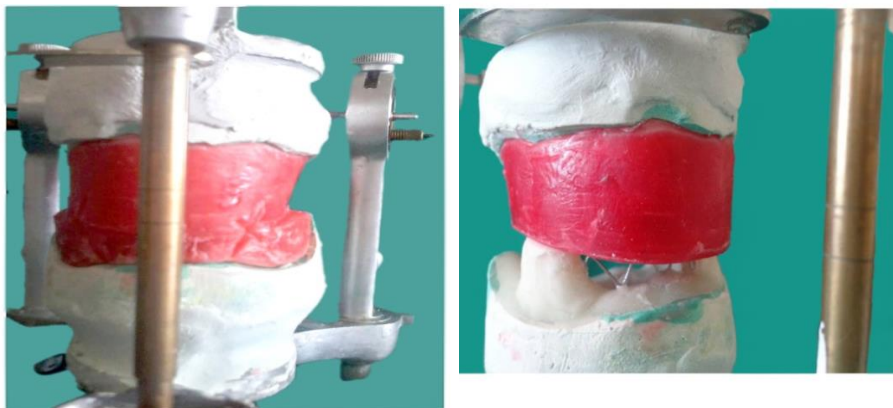


Fig 4:- Tentative jaw relations recorded and wire loops made on lower denture base to maintain vertical dimension

- Neutral zone recording was done using a mixture of green stick modelling compound and impression compound in the ratio of 7:3 (w/w). To record neutral zone, the patient should be in upright and comfortable position. The mixture of green stick and impression compound (admix material) was placed on the lower recording base and it was then inserted into the patient's mouth. Patient was instructed to perform functional movements such as swallowing, licking lips, sucking, puckering, smiling, pronouncing words and these movements were repeated until the material had set. The displaced excess material was removed and thus the boundary of neutral zone space was limited by functional movements of orofacial musculature (Fig. 5). A silicone putty (Aquasil, Soft putty, Dentsply, India) index was made to preserve the neutral zone on the cast. The putty index had two components. One is facial matrix and the other one is lingual matrix. Now lower occlusal rim along with recording base was replaced by the other prefabricated denture base and prtty index was again placed on the cast to confine the neutral zone. Melted base plate wax was then poured into the space limited by the putty index and a duplicate wax occlusal rim was thus fabricated.
- Facebow transfer was done to orient the maxillary cast to a semi adjustable articulator similar to the patient's opening axis. The upper and lower occlusal rim were inserted in the patient's mouth to verify vertical dimension

of occlusion and the rims were fused together at centric relation. The master casts were then mounted in the semi-adjustable articulator. Proper shade and teeth mould was then selected accordingly. Teeth arrangement was done in balanced occlusion using non-anatomic teeth to minimize

horizontal component of forces and thus improved stability of the denture on a flat resorbed ridge. Bucco-lingual position and occlusal plane of mandibular teeth was verified using putty index.

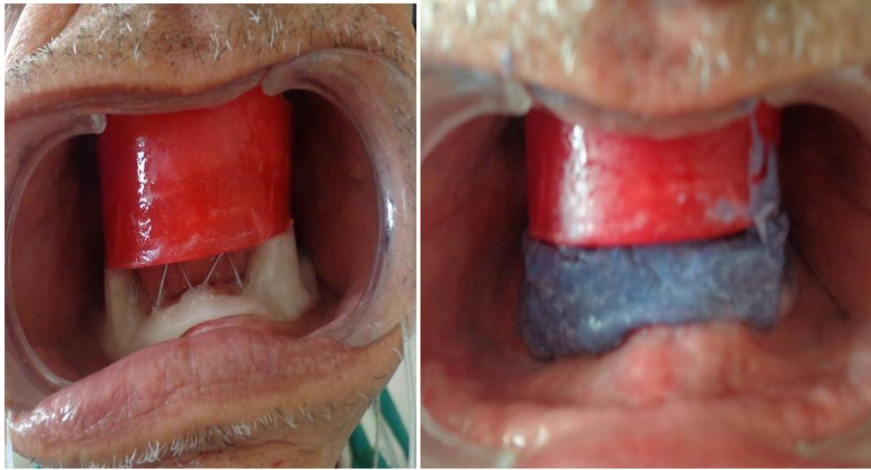


Fig 5:- Recording of neutral zone

- Try in was done to verify stability and retention of denture base, vertical dimension, phonetics, centric relation, aesthetics and necessary correction was done accordingly. Now, wax apical to denture teeth was carefully removed from both facial and lingual aspect of mandibular trial denture. Zinc oxide eugenol paste was applied on the facial aspect of mandibular trial denture and carefully inserted into the patient's mouth. The patient was instructed to pucker his lips, smile widely and these functional movements were repeated for several times. Trial denture was removed from patient's mouth and the external impression was checked. External impression of lingual aspect of mandibular trial denture was recorded in similar way. Evaluation of denture flange extensions and dimensions was done properly. Excess impression

material was trimmed and any material that covered the denture teeth was removed carefully.

- After try in procedure the denture was processed with heat cure acrylic resin (DPI Heat cure, The Bombay Burmah Trading Corporation, Mumbai, India). Final acrylic denture was thus fabricated after proper finishing and polishing and inserted into the patient's mouth. The patient was instructed about the maintenance of complete denture and advised to come after 24 hours following the denture insertion. The retention, stability and support were improved significantly and the patient was happy with his newly fabricated denture. There was significant change in the facial profile after fabrication of complete denture prosthesis (Fig. 6 and Fig. 7).

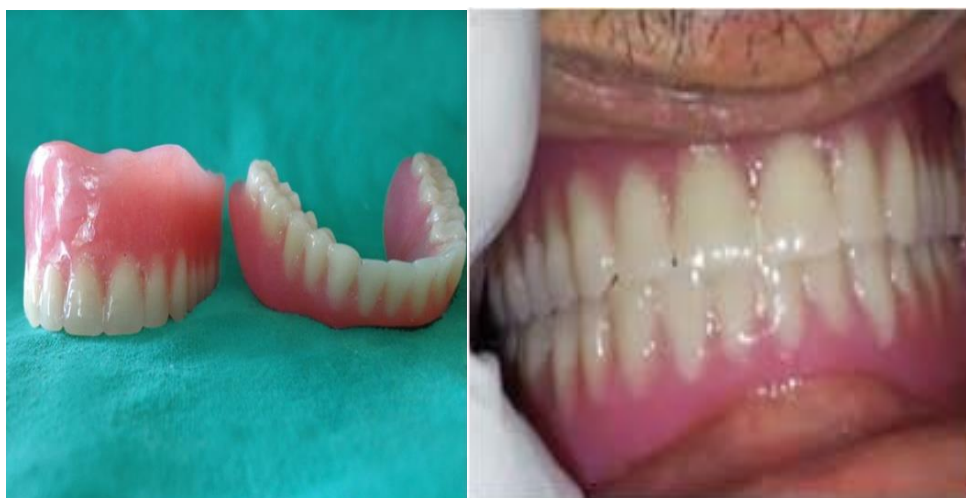

Fig 6:- Final Prosthesis and intra-oral view of the resultant prosthesis

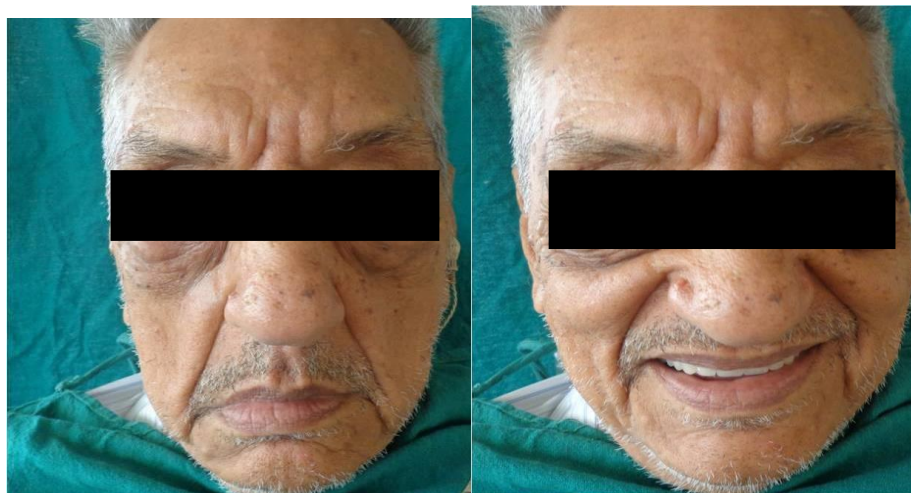

Fig 7:- Pre-operative and Post-operative

III. DISCUSSION

Prosthetic management of a patient with compromised residual alveolar ridges needs special consideration. Displaceable fibrous tissue, resorbed alveolar ridge significantly compromise denture stability, retention and support. Selection of treatment modality depends on patients' general health, clinical condition of residual alveolar ridges, financial capacity and skill of the clinician. Surgical excision of flabby tissue is considered when adequate bone height is available but in many cases it decreases the sulcus depth. Ridge augmentation by grafting is an invasive procedure and may cause rejection of graft material.

Desjardins and Tollman (1974)^[4] popularized the idea of injecting sclerosing agent to make a hypermobile tissue firm. The disadvantages were anaphylactic reactions, patient discomfort, loss of firmness and technique sensitivity.

The key to manage flabby ridge conservatively lies in the principle of impression technique. The goal of impression is to record the non-displaceable tissue in compression to obtain optimal support and to record the displaceable flabby ridge without distortion. Liddlelow^[5] in 1964 described a technique where two separate impression materials were used in a custom tray (plaster of paris over flabby ridge and zinc oxide eugenol paste over non displaceable tissue).

A window technique was proposed by Watson^[6] in 1970 where he made a window in the custom tray over the flabby tissue and used impression plaster for flabby ridge and zinc oxide eugenol paste for the healthy denture bearing area. A similar technique was described by Zafrulla khan et al^[7] in 1981 where they used regular body impression material for healthy tissue. Watt and McGregor^[8] in 1986 used impression compound to a modified custom tray and a zinc oxide eugenol wash impression was taken.

A highly resorbed and abused residual ridge significantly compromise denture stability. Chander S et al^[9] in 2007 used tissue conditioners as functional impression material. The advantages to use tissue conditioner are it flows readily by means of functional stresses and closely adapt to

the denture foundation area. The concept of neutral zone was first introduced by Sir Wilfred Fish in 1933.

The principle of neutral zone recording in construction of complete denture is that to locate an area in the edentulous mouth where the teeth should be positioned so that the forces exerted by muscles will tend to stabilize the denture rather unseat it. Tench et al^[10] first introduced the use of modelling compound to record neutral zone. The materials used for recording of neutral zone should have sufficient flow and reasonably slow setting so that it can be properly moulded by oral musculatures.

IV. CONCLUSION

There is no single technique to rehabilitate compromised residual alveolar ridges. A multidisciplinary approach is required to achieve optimal success. Surgical removal of soft tissue and implant supported prosthesis may not be possible in all situations. In that case, a conservative approach using modified impression technique, neutral zone concept provides the basic triad of a successful denture prosthesis that is retention, stability and support.

REFERENCES

- [1]. Crawford RW, Walmsley AD. A review of prosthodontics management of fibrous ridges. *Br Dent J* 2005; 199:715-9.
- [2]. Kelly E. Changes caused by a mandibular removable partial denture opposing a maxillary complete denture. *J Prosthet Dent* 1972; 27: 140-150.
- [3]. Douglas Allen Atwood. Some clinical factors related to rate of resorption of residual ridges. *J Prosthet Dent* 1962; 12(3): 441- 450.
- [4]. Desjardins RP, Tolman DE. Etiology and management of hypermobile mucosa overlying the residual ridge. *J Prosthet Dent* 1974; 32: 619- 38.
- [5]. Liddlelow KP. The prosthetic treatment of the elderly. *Br Dent J* 1964; 117: 307-315.
- [6]. Watson RM. Impression technique for maxillary fibrous ridge. *Br Dent J* 1970; 128: 552.

- [7]. Khan Z, Jagers J, Shay J. Impressions of unsupported movable tissues. JADA 1981; 103: 590-92.
- [8]. Lynch CD, Allen PF. Management of the flabby ridge: using contemporary materials to solve an old problem. Br Dent J 2006; 200:258-261.
- [9]. Chander, S., Hill, M., Moore, D. and Morrow, L. (2007) Tissue Conditioning Materials as Functional Impression Materials. European Journal of Prosthodontics and Restorative Dentistry, 15, 67-71.
- [10]. Victor E. Beresin. The neutral zone in complete denture. 1973; 5: 53.