

# Rapid Maxillary Expansion: A Review

Sharath Kumar Shetty<sup>1</sup>, Mahesh Kumar Y<sup>2</sup>, Harish Gowda K<sup>3</sup>

1. Professor & HOD, Department of Orthodontics & Dentofacial Orthopaedics, K.V.G Dental College & Hospital, Sullia, Karnataka, India
2. Professor, Department of Orthodontics & Dentofacial Orthopaedics, K.V.G Dental College & Hospital, Sullia, Karnataka, India
3. Post Graduate Student, Department of Orthodontics & Dentofacial Orthopaedics, K.V.G Dental College & Hospital, Sullia, Karnataka, India \*Corresponding author

**Abstract:-** Arch expansion is a method of gaining space. An apparently complex yet relatively simple procedure in orthodontics is Palatal expansion. The correction of transverse maxillary deficiency can be an important component of an orthodontic treatment plan. Rapid Maxillary expansion (RME) is a skeletal type of expansion that involves the separation of the mid-palatal suture and movement of the maxillary shelves away from each other. RME effects the maxillary complex, palatal vaults, maxillary anterior and posterior teeth, adjacent periodontal structures to bring about an expansion in the maxillary arch. The majority of dental transverse measurements changed significantly as a result of RME. This review article provides detailed information about rapid maxillary expansion and the appliances used commonly for RME.

**Keywords:-** Palatal Vault, Rapid Maxillary Expansion, Maxillary Arch, Arche Width.

## I. INTRODUCTION

Rapid maxillary expansion (RME) is a dramatic procedure used for gaining space in the maxillary arch. Emerson Angell in 1860<sup>1</sup>, first described the rapid maxillary expansion and later it was re-popularized by Haas. Expansion of the maxilla, by the use of fixed or removable expansion appliances, is mainly used in orthodontics for the correction of malocclusion. Expansion is primarily used for the correction of posterior crossbites occurring as a result of insufficient maxillary width. It is particularly important to correct the deviation of mandible while function and deficient maxillary arch width in early dentition development, which, if not corrected, may have undesirable consequences on facial symmetry and function of TMJ. Rapid Maxillary expansion occupies unique niche in orthodontic treatment. The elimination of transverse maxillary deficiency should include as an important part of an orthodontic treatment plan. Growth is normally complete by the age of 17 years and the mean transverse, growth between the age of four years and adulthood is 6.9 mm. Maxilla will grow in small amount transversely throughout the life, it is more likely that a crossbite encountered in the permanent dentition will not get corrected by itself<sup>2</sup>.

## II. ANATOMY OF AXILLA

The tenacity of circum maxillary attachments due to buttressing is strong posterosuperior- medially and posterosuperior laterally. A palatine bone forms an intimate relationship with maxilla to form complete hard palate (or) floor of nose and greater part of lateral wall of nasal cavity. It articulates anteriorly with maxilla through transverse palatal sutures and posteriorly through pterygoid process of the sphenoid bone. The interpalatine suture joins the two palatine bones at their horizontal plates and continuous as inter maxillary sutures. These sutures form the junction of three opposing pairs of bones: the premaxillae, maxilla, and the palatine. The entire forms mid-palatal suture.

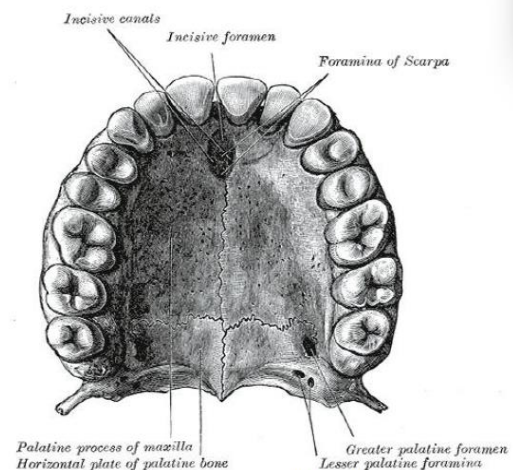


Fig 1. Anatomy of Maxilla

## III. SUTURES

The maxilla is connected to the cranium and cranial base by a number of sutures<sup>3</sup>

- Nasomaxillary Suture
- Frontomaxillary Suture
- Zygomaticotemporal Suture
- Lacrimomaxillary Suture
- Ethmoidomaxillary Suture
- Vomeromaxillary Suture

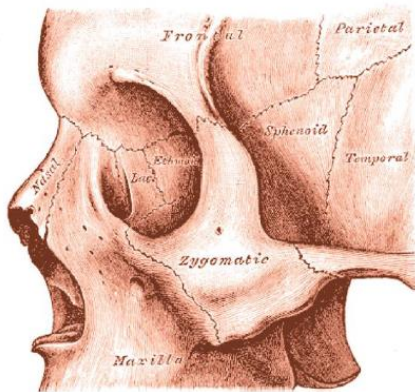


Fig 2. Sutures in the maxillofacial region

Mid Palatine Suture plays a key role in R.M.E<sup>4</sup> Shape of suture varies with age (Fig.3 and 4)

- 1) Infancy - Y-shape
- 2) Juvenile - T-shape
- 3) Adolescence - Jigsaw puzzle

As sutural patency is vital to R.M.E, it is important to know when does the suture closes by synostosis<sup>5</sup>. On an average 5% of suture in closed by age 25 yrs. Earliest closure occurs in girls aged 15 yrs. Greater degree of obliteration occurs posteriorly than anteriorly. Ossification comes very late anterior to incisive foramen<sup>2</sup> this is important when planning surgical freeing in late instances of RME.<sup>6</sup>

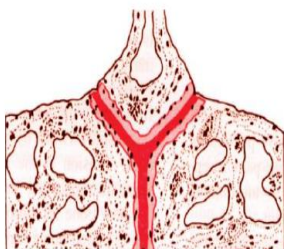


Fig 3. Mid palatine suture in infancy

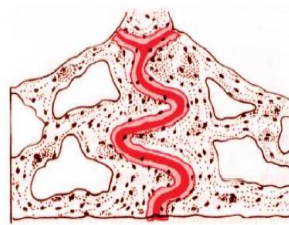


Fig 4. Mid palatine suture in early adolescence

➤ *Factors to be considered prior to expansion*

Important factors to be considered in Rapid Maxillary Expansion:

- Rate of Expansion: Active expansion of 0.3 -0.5mm is completed in 2-4 weeks, with some time for the cellular response of osteoclasts and osteoblasts cells.
- Form of Appliance: As the thrust is delivered to the teeth at the inferior free borders of the maxilla, expansion must reach to the basal portions. The form of appliance will play an important role in this effort, according to its rigidity or flexibility, i.e. anchorage or control of tipping.
- Age and Sex of the patient: expansion differs in both the sexes because of increasing rigidity of facial skeletal with age.
- Discrepancy between maxillary and mandibular: If discrepancy between first molars & bicuspid width is 4mm or more RME indicated.
- Severity of cross bite i.e. number of teeth involved.

- Initial angulation of molars or premolars: When the maxillary molars are buccally inclined, conventional expansion will tip them further into the buccal musculature and if the mandibular molars are lingually inclined, the buccal movement to upright them will increase the need to widen the upper arch.
- Assessment of roots of deciduous tooth.
- Physical availability of space for expansion.
- Nasal Obstruction: All patients considered for RME should be examined for nasal obstruction and, if obstruction is found, they should be referred to an otolaryngologist before orthodontic treatment.
- Medical history: The efficacy of maxillary expansion depends on suture patency, since the flexibility of craniofacial complex is adapted to mechanical changes. Hence medical conditions altering these should be considered.
- Metabolic disorders: Many metabolic disorders are found to be associated with suture synostoses which include hyperthyroidism, hypo phosphatemic vitamin D-resistant rickets, and mucopolysaccharidoses and mucopolipidoses. These disorders are mostly associated with bone metabolism. Maxillary expansion would be futile even in young patients if they are suffering from any of these diseases.
- Periodontal Type: Gingival condition is also important because a thin and delicate gingiva might be prone to recession after surgical trauma or injury<sup>7</sup>.
- Mucogingival Health: Orthodontic tooth movement has significant effect on the mucogingival tissues and hence it is important to assess the periodontal health of the patient before performing RME.

➤ *Effect of RME on maxillary and mandibular complex*

- Maxillary skeletal effect: When viewed occlusally, Inoue found that the opening of the midpalatine suture was nonparallel and triangular with maximum opening at incisor region and gradually diminishing towards the posterior part of palate (fig.5). Viewed frontally, the maxillary suture separates supero-inferiorly in a nonparallel manner.<sup>8</sup> It is pyramidal in shape with the base of pyramid located at the oral side of the bone.
- Maxillary halves: Haas<sup>9</sup> and Wertz<sup>10</sup> found the maxilla to be frequently displaced downward and forward.
- Palatal vault: Haas<sup>9</sup> reported that the palatine process of maxilla was lowered as a result of outward tilting of maxillary halves.

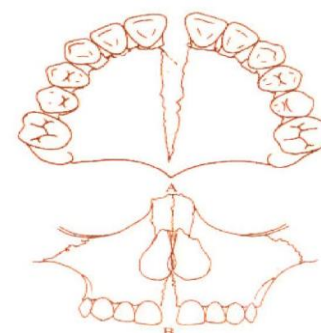


Fig 5. Effects of RME on mid palatine suture

**Alveolar process:** Because bone is resilient, lateral bending of the alveolar processes occur early during RME, which rebounds back after a few days.<sup>11</sup>

**Maxillary anterior teeth:** Spectacular changes accompanying RME is the opening of a diastema between the maxillary central incisors.(fig.6) It is estimated that during active suture opening, the incisors separate approximately half the distance the expansion screw has been opened,<sup>9</sup> but the amount of separation between the central incisors should not be used as an indication of the amount of suture separation.<sup>10</sup> This diastema is self-corrective due to elastic recoil of the transseptal fibres.

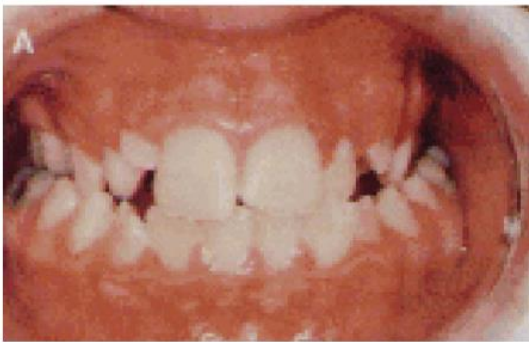

Fig 6. Effects of RME on anterior teeth

**Maxillary posterior teeth:** There is buccal tipping and extrusion of the maxillary molars. The posterior maxilla expands less readily because of the resistance produced by the zygomatic buttress and pterygoid plates.

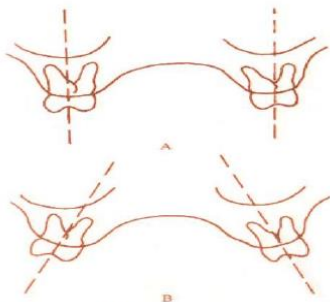


Fig 7. Effects of RME on maxillary posterior teeth

**Effect of RME on mandible:** There is a concomitant tendency for the mandible to swing downward and backward.<sup>8</sup>

- **RME and nasal airflow:** Anatomically, there is an increase in the width of the nasal cavity immediately following expansion thereby improves in breathing. The nasal cavity width gain averages of 1.9 mm, but can be as wide as 8 to 10 mm.<sup>12</sup> It is important for the clinician to remember that the main resistance to midpalatal suture opening is probably not the suture itself, but in the surrounding structures particularly the sphenoid and zygomatic bones.<sup>8</sup>

➤ **Indications for RME**

- Severe maxillary constriction (narrow maxillary base or wide mandible).
- Unilateral or bilateral posterior crossbites.
- Anteroposterior discrepancies.

- Patients with Class III malocclusions & borderline skeletal and pseudo Class III problems.
- Cleft lip and palate patients with collapsed maxillae.
- To gain arch length in patients who have moderate maxillary crowding.

➤ **Contraindications for RME**

- Uncooperative individuals.
- Single tooth cross bite.
- Anterior open bite.
- Steep mandibular plane angle and convex profile.
- Skeletal asymmetry of the maxilla or mandible.
- Adults with severe anteroposterior and vertical skeletal discrepancies

➤ **Hazards of RME**

- Oral hygiene
- Length of fixation
- Dislodgement and breakage
- Tissue damage
- Infection
- Failure of suture to open

➤ **Appliances for RME**

These are banded and bonded appliances. The banded appliances are attached to teeth with bands on the maxillary first molar and first premolars. The banded appliances are hygienic as there is no palatal coverage. The banded RME are of two types:

- a) Tooth & tissue borne
  1. Derichweiler
  2. Hass
- b) Tooth borne
  1. Isaacson
  2. Hyrax

➤ **Tooth borne RME**

They consist of only bands and wires without any acrylic covering.

**HYRAX expander:** It is a tooth borne appliance, which was introduced by William Biederman in 1968. This type of appliance makes use of a special screw called HYRAX (Hygienic Rapid Expander). The Hyrax Expander (Fig.8) is essentially a nonspring loaded jackscrew with an all wire frame.<sup>14</sup> The screws have heavy gauge wire extensions that are adapted to follow the palatal contours and soldered to bands on premolar and molar. The main advantage of this expander is that it does not irritate the palatal mucosa and is easy to keep clean. It is capable of providing sutural separation of 11mm within a very short period of wear and a maximum of 13 mm can also be achieved. Each activation of the screw produces approximately 0.2 mm of lateral expansion and it is activated from front to back.



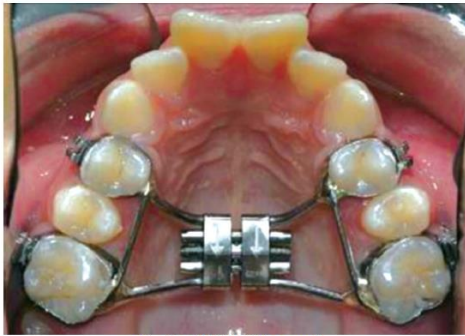

Fig 8. HYRAX Expander

**Issacson expander:** It is a tooth borne appliance without any palatal covering.(fig.9) This expander makes use of a spring loaded screw called Minne expander (developed by university of Minnesota, dental school), which is soldered directly to the bands on first premolar and molars.<sup>14</sup> The Minne expander is a heavily calibrated coil spring expanded by turning a nut to compress the coil. Two metal flanges perpendicular to the coil are soldered to the bands on abutment teeth. The Minne expander may continue to exert expansion forces after completion of the expansion phase unless they are partly deactivated.

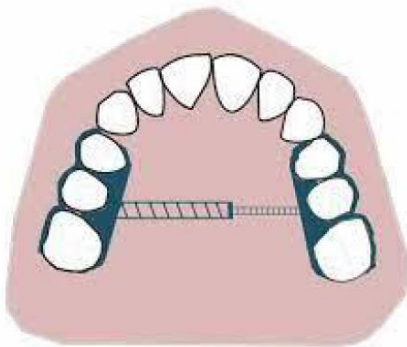


Fig 9. Issacson Expander

➤ *Tooth and tissue borne RME*

They consist of an expansion screw with acrylic abutting on alveolar ridges. Haas, in 1970, gave the following advantages of tooth and tissue RME:

- Produces more parallel expansion
- Less relapse
- Greater nasal cavity and apical base gain
- More favourable relationship of the denture bases in width and frequently in the anteroposterior plane as well
- Creates more mobility of the maxilla instead of teeth.

➤ *Disadvantage of tooth and tissue borne RME*

These tooth and tissue borne RME tend to have higher soft tissue irritation.

➤ *Types of tooth and tissue borne RME*

- **Haas:** The basis for the rapid expansion procedure is to produce immediate midpalatal suture separation by disruption of the sutural connective tissue. The rapid palatal expander as described by Haas is a rigid appliance designed for maximum dental anchorage that uses a

jackscrew to produce expansion in 10 to 14 days.<sup>15</sup> He believed that this will maximize the orthopaedic effects and forces produced by this appliance have been reported in the range of 3 to 10 pounds. (fig.10)

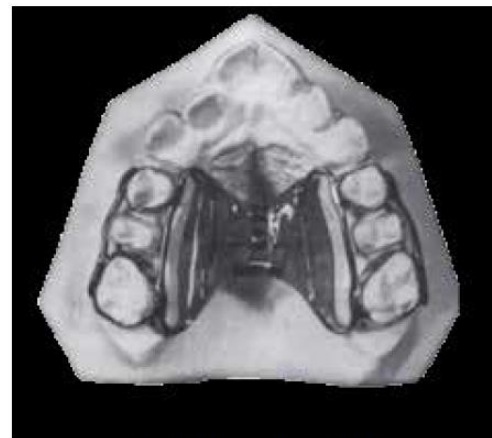

Fig 10. Haas Expander

**Derichsweiler:** The first premolar and molars are banded. Wire tags are soldered to these bands and then inserted to the split palatal acrylic, which contains the screw.(fig.11)

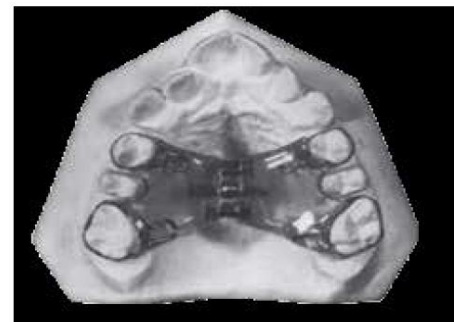

Fig 11. Derichsweiler appliance

➤ *Construction guide lines*

- Ideally the screw should be placed as high in palatal vault as possible.
- The entire appliance component should be kept away from tissue surface.
- Centre of screw must be waxed out to keep it clear of acrylic.

➤ *Activation schedule*

1. Schedule by Timms<sup>13</sup>

Patients <= 15 yrs.: 90 degree rotation in morning and evening.

>= 15 yrs.: 45 degree activation 4 times per day.

>= 20 yrs.: 45 degree rotation in morning and evening.

2. Schedule by Zimring and Isaacson<sup>9</sup>

- **Young growing patients:** Two turns per day for 4- 5 days, followed by one turn per day till expansion is achieved.
- **Non growing adults:** Two turns per day for 2 days, then one turn per day for 5-7 days, followed by one turn every alternate day, till expansion is achieved.
- **Mc Namara and Brudon:** Prefer a turn once per day activation schedule till expansion is obtained, in order to

avoid nasal distortion (saddle nose deformity) which has been associated with two expansions per day protocol.<sup>16</sup>

#### ➤ *CBCT to assess changes after RME treatment*

Cone- Beam Computed Tomography is an innovative diagnostic method in dentistry as it gives high dimensional accuracy of the facial structures and a authentic method for quantifying the position of the maxillary halves, tipping of teeth, bone formation at the suture, alveolar bone resorption and other consequences of maxillary expansion.<sup>17</sup> Some studies have been done to assess the effects of Rapid Maxillary Expansion on the periodontal and skeletal changes. Before CBCT, the changes obtained by RME were assessed by dental model and conventional radiographs but with CBCT, clinicians can accurately assess the three dimensional changes in the skeletal structures quantitatively. Also CBCT studies emphasize that tipping caused by maxillary expansion was due to the decrease in buccal bone thickness. One can see a triangular shaped, radiolucent area with its base facing the anterior nasal spine with reduced bone strength. At the same time CT confirms the orthopaedic splitting of the maxilla, it subsequently records midpalatal suture reorganization, which occurs during the retention phase.<sup>18</sup>

#### IV. ADVANCEMENT IN TREATMENT

#### ➤ *SARPE<sup>19,20</sup> (Surgically Assisted Rapid Palatal Expansion)*

During skeletal expansion, the buttressing effect of zygomatic and sphenoid bones at their point of attachment to the maxilla gives the main resistance and form the integrity of the midpalatal suture. With SARPE, these attachments are surgically detached which allows expansion to be easily achieved using a conventional RME appliance. Before surgery, fixed appliances can be used to move apart the roots of the central incisors to prevent the damage of roots by midline maxillary surgical cut. Expansion is typically carried out at a rate of 0.5 mm a day and patients develop a significant midline diastema, which they must be warned about. Probably because of the inelasticity of the palatal mucoperiosteum there will be more chances of relapse after surgical correction so the overcorrection is required to compensate the relapse. SARPE is the technique of choice in patients who do not have co-existing sagittal and vertical maxillary discrepancies which may require maxillary surgery at a later date.

#### ➤ *Segmental Maxillary Surgery<sup>20</sup>*

To expand the maxilla, Le fort 1 osteotomy technique should be performed simultaneously with surgical cut along the midpalatal suture. The maxillary halves are then parted and positioned in the new place. Expansion is limited due to the relative inelasticity of palatal mucoperiosteum. Maxillary incisor roots can be separated with fixed orthodontic treatment, to ease to make surgical midline cut like SARPE.

#### V. CONCLUSION

RME is a technique of choice in several cases like moderate to severe transverse discrepancy. This helps us to increase the arch length in moderate crowding cases where arch length is deficient. Orthopaedic transverse correction can be done by tipping of posterior teeth buccally along with separation of midpalatal suture. Overcorrection is required to compensate the relapse. Nowadays, CBCT has being used to assess the accurate three dimensional orthopaedic changes after RME treatment. There are various designs for RME appliances available to the orthodontic practitioner, ranging from banded designs, bonded designs, tooth, tissue, bone-retained RME or hybrid designs. The literature shows various uses of RME appliances ranging broadly from treatment of a constricted maxilla to bedwetting. The success of the RME treatment is dependent on careful appliance design and the successful splitting of the midpalatal suture.

#### REFERENCES

- [1]. Timms DJ. The dawn of rapid maxillary expansion. *Angle Orthod* 1999 Jun;69(3):247-250.
- [2]. Kumar SA, Gurunathan D, Muruganandham SS. Rapid Maxillary Expansion: A Unique Treatment Modality in Dentistry. *Journal of Clinical and Diagnostic Research*.2011 August, Vol-5(4):906-911.
- [3]. Leonardi R, Sicurezza E, Cutrera A, Barbato E. Early posttreatment changes of circum maxillary sutures in young patients treated with rapid maxillary expansion. *The Angle Orthodontist*. 2011 Jan;81(1):36-41.
- [4]. Melson B. Palatal growth study on human autopsy material: A histologic micro radiographic study. *Am J Orthod*1975 ; 68: 42-54.
- [5]. Persson M, Thilander B. Palatal suture closure in man from 15 to 35years of age. *Am J Orthod*1977;72:42-52
- [6]. Bjork A and Skieller V. Growth in width of the maxilla by the implant method. *Scand J PlastReconst Surgery* 1974;8-22-33.
- [7]. Suri and Taneja, Surgically assisted rapid palatal expansion: A literature review, *American Journal of Orthodontics and Dentofacial Orthopaedics* Volume 133, Number 2 776-780.
- [8]. Bishara SE, Staley RN. Maxillary expansion: Clinical implication. *Am J Orthod Dentofacial Orthop* 1987 Jan;91(1):3-14.
- [9]. Haas AJ. Rapid expansion of the maxillary dental arch and nasal cavity by opening the midpalatal suture. *Angle Orthod* 1961;31: 73-90.
- [10]. Wertz RA. Skeletal and dental changes accompanying rapid midpalatal suture opening. *Am J Orthod* 1970 Jul;58(1):41-66.
- [11]. Isaacson RJ, Wood JL, Ingram AH. Forces produced by rapid maxillary expansion. I. Design of the force measuring system. *Angle Orthod*1964;34:256-260
- [12]. Gray LP. Results of 310 cases of rapid maxillary expansion selected for medical reasons. *J LaryngolOtol* 1975 Jun;89(6): 601-614.

- [13]. Rapid maxillary Expansion <sup>2</sup>Donald J. Timmis.
- [14]. Isaacson RJ, Wood JL, Ingram AH. Forces produced by rapid maxillary expansion. I. Design of the force measuring system. *Angle Orthod* 1964;34:256-260. 21. Gray LP. Results of 310 cases of rapid maxillary expansion selected for medical reasons. *J Laryngol Otol* 1975 Jun;89(6): 601- 614.
- [15]. Haas AJ. The treatment of maxillary deficiency by opening the midpalatal suture. *Angle Orthod* 1965 Jul;35:200-217.
- [16]. Altug-Atac AT, Atac MS, Kurt G, Karasud HA. Change in nasal structures following orthopaedic and surgically assisted rapid maxillary expansion. *International journal of oral and maxillofacial surgery*. 2010 Feb 28;39(2):12 -35.
- [17]. Ribeiro GL, Locks A, Pereira J, Brunetto M. Analysis of rapid maxillary expansion using cone-beam computed tomography. *Dental Press Journal of Orthodontics*. 2010 Dec;15(6):107-12.
- [18]. Khan MA, Hussain SS. The clinical application of cone beam CT in orthodontics. *Pak Ortho J*. 2014;6(1):32-7.
- [19]. Susami T, Kuroda T, Amagasa T. Orthodontic treatment of a cleft palate patient with surgically assisted rapid maxillary expansion. *cleft palate craniofacial journal*. 1996 Sep;33(5).
- [20]. Gill D, Naini F, McNally M, Jones A. The management of transverse maxillary deficiency. *Dent Update*. 2004 Nov;31(9):516-23.