

# Effect of Milwaukee Brace in Adolescent Idiopathic Scoliosis

Sangita Nayak

**Abstract:-** The spine presents two characteristics significant to Milwaukee brace use, its varying susceptibility to both deforming and corrective influence and its relative inaccessibility. The Milwaukee brace can apply longitudinal as well as transverse forces to correct the spinal deformity. This study intended to evaluate the effectiveness of Milwaukee brace on progression control as well as correction of scoliosis.

**Methodology:** All the patients diagnosed with AIS.04(four) scoliotic patients, 02 males and 02 females of age group 08-14 who fulfilled the following criteria were recruited and reviewed. After assessment the patient were asked to use Milwaukee brace was fabricated and advised to the patients to use 23 hours per day with exercises. After 1 year radiographic data were taken for evaluation

**Results:** All data showed clinical improvement in Cobb's angle, pelvis symmetry, shoulder level by using Milwaukee braces. The best response to brace treatment occurred when treatment was begun before onset of puberty. Longer curves corrected best. Curves of less than 40 degree were satisfactorily treated without surgery. The x-rays (orthoscanogram) was taken of 4 patients without braces who are using Milwaukee braces 7-12 months ago. In patient 1 there is no pelvic asymmetry. There is improvement of pelvic symmetry in all three patients as compared with previous x-rays. Lateral trunk shift measurement also done. It was also as compared with previous x-rays.

**Conclusion:** After analysis of data it was confirmed that Milwaukee brace when used 23 hours per day is effective in preventing progression of higher curves.

**Keywords:-** Milwaukee brace, scoliosis, treatment.

## I. INTRODUCTION

Scoliosis is characterized by sideways curve along with vertebral and trunk rotation. If it will remain untreated, it may progress and in severe case it will create various morbidity problem. For non-operative treatment, brace is the only effective method in preventing curve progression.

Any spinal curvature is improved effectively by utilizing corrective forces, distraction, and three point axially directed pressure. For greater the curve more distraction component is required. The Milwaukee brace differs from its predecessors in providing both active as well as passive correction.

Proper assessment is necessary for orthotic management. In this paper, we use radiographs (trunk) to calculate the thoracic trunk shift and overall balance summation, Cobb's angle, in scoliosis patients.

Aim of the study- To prevent further progression of curve and improve cosmetic appearance by maintaining alignment of the whole spine structure and balance during period of growth. This study aimed to estimate the effectiveness of the brace by analyzing some parameters.

## II. METHODOLOGY

Four AIS patients (two girls and two boys) within age group 08- 14 years were recruited in this study (Table 1). The value of Cobb angle in scoliotic patients was between 20° and 40° and apical vertebra was below T<sub>1</sub>. All the scoliotic patients were treated with a Milwaukee brace.

Subjects with Idiopathic scoliosis, skeletally immature patient, Risser's sign 0-3 were included in the study. Exclusion criteria were as follows: Subjects with Skeletal age >Risser's sign 3. Rigid curves, previous spinal surgery, The following parameters were done-Radiographic analysis (orthoscanogram), decompensation measurement, lateral trunk shift measurement, overall balance summation, Adams forward-bending test. A written consent form was signed by the parents of the participants before data collection. After proper assessment, those who have been fulfilled the inclusion criteria were fitted with Milwaukee brace. Before fitting x-ray was taken. After 6 month strap adjustment was done. Data collection was done at svnirtar radiographic measurement was taken both pre and post use of Milwaukee brace (after 1 year).

| Gender | Age    | Primary curve | Secondary curve |
|--------|--------|---------------|-----------------|
| male   | 9years | T6(LT)        | NO              |
| female | 14year | T5(LT)        | L2              |
| female | 12year | T5(RT)        | L1              |
| male   | 8year  | T4(LT)        | NO              |

Table 1: Demographic characteristics of the patients

### III. FITMENT WITH APPLIANCE

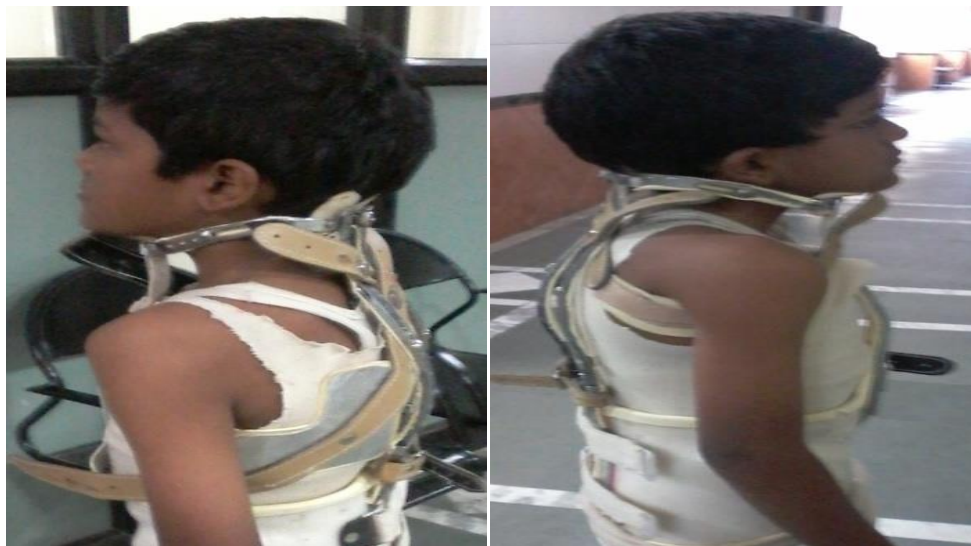

Image 1: (MEDIAL & LATERAL VIEW)

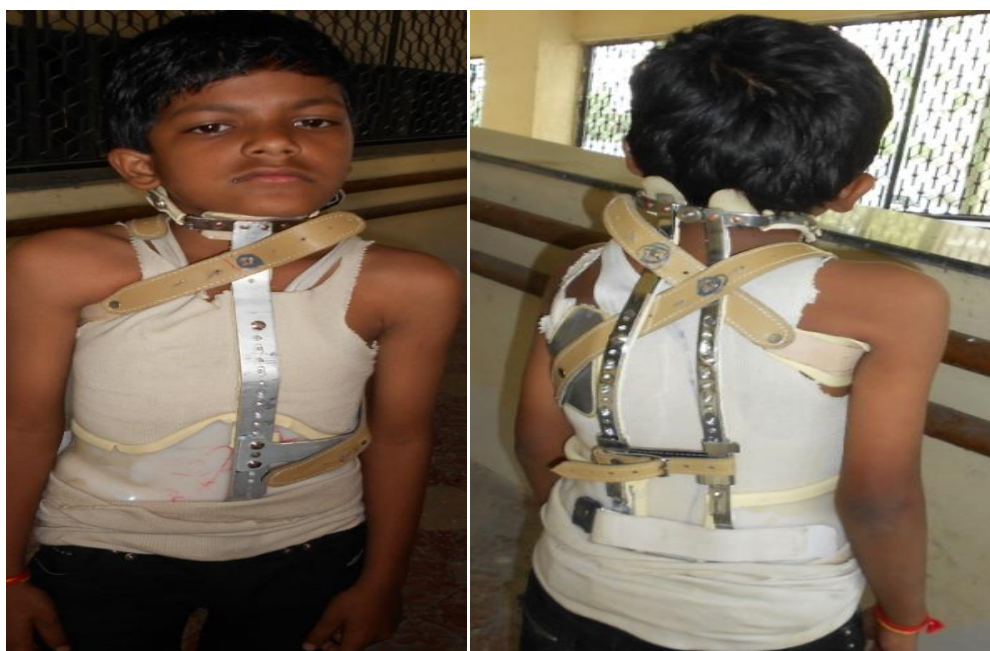

Image 2: (ANTERIOR & POSTERIOR VIEW)

- **Radiographic analysis (Orthoscanogram)**-The full-length upright standing lateral and poster anterior radiographs of each patient were evaluated with regard to the following measurements:

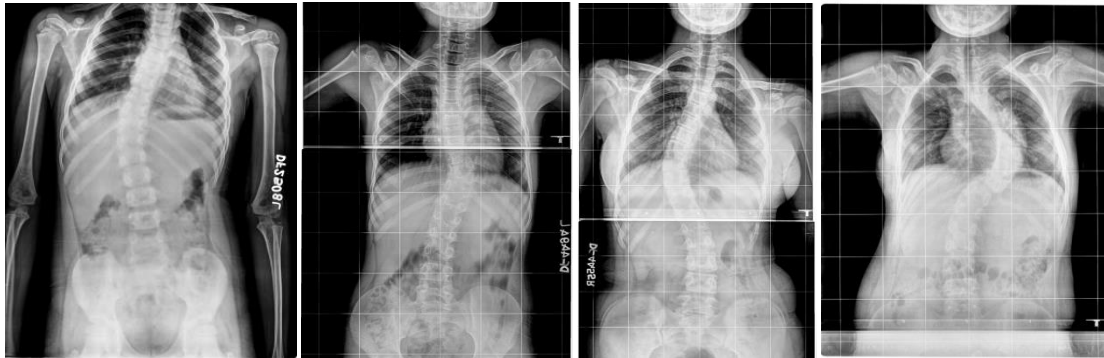


Image 3: (Orthoscanograms of patients)

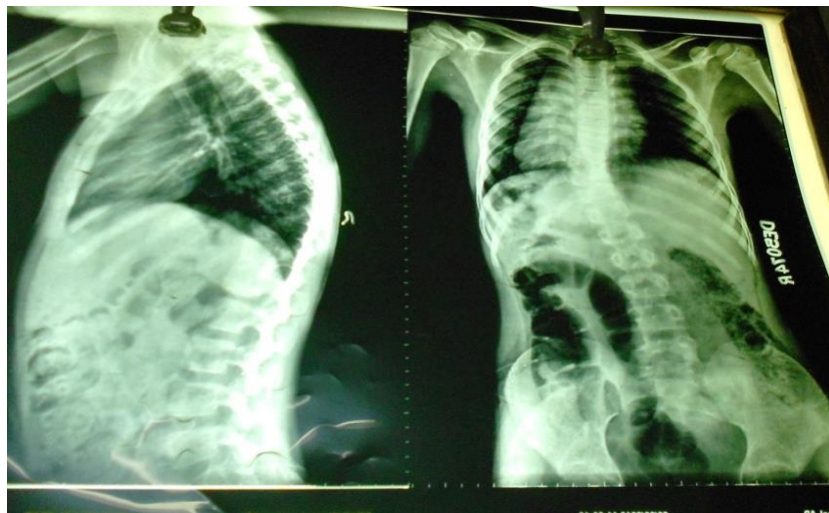


Image 4: (A-P & LATERAL VIEW ,WITHOUT ORTHOSIS)

- Decompensation measurement
- Lateral trunk shift measurement
- Overall balance summation

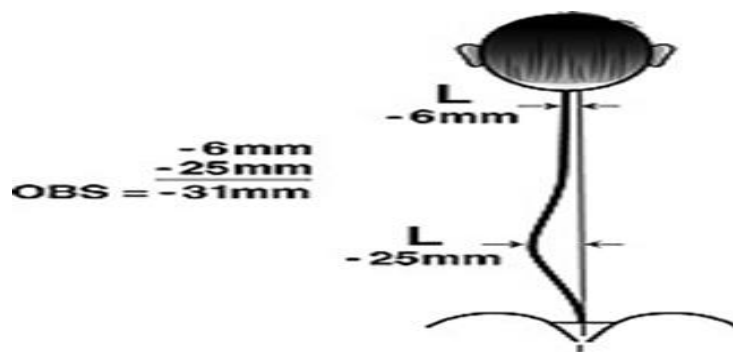


Image 5

- Cobbs angle

**IV. RESULTS**

The patient reported an average daily wearing time of 23 hours. The full-length upright standing lateral and poster anterior radiographs of each patient were evaluated after 1 year either with the patient wearing or not wearing the Milwaukee. Table 2 summarizes the radiographic results of brace treatment for the 1 year of treatment. After 1 year use of milwaukee brace reduction was nearly half that of the original scoliosis. The patient also reported relief of back pain using brace. Some significant differences were seen

between pre and post use of Milwaukee brace in adolescents idiopathic scoliotic subjects.

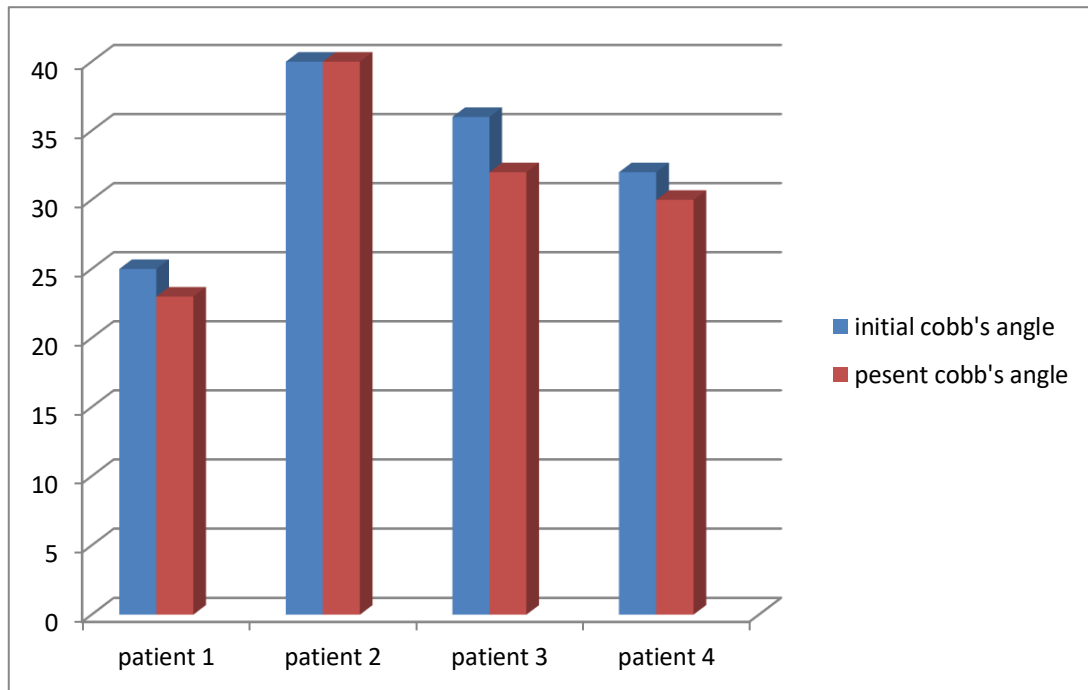
All the showed clinical improvement in Cobb's angle, pelvissymmetry. Shoulder level by using Milwaukee braces. The x-rays (orthoscanogram) was taken of 4 patients without braces who are using Milwaukee braces 7-12 months ago. In patient 1 there is no pelvic asymmetry. There is improvement of pelvic symmetry in all three patient as compared with previous x-rays. Lateral trunk shift measurement also done. it was also as compared with previous x-rays. The best response to brace treatment occurred when

treatment was begun before iliac apophyses were capped. Longer curves corrected best. Curves of less than 40 degree

were satisfactorily treated without surgery. The high thoracic curves gave the poorest response to treatment.

| No of patients | Cobbs angle before 6 month | Cobbs angle at present | Lateral trunk shift before 6 month | Lateral trunk shift at present | OBS    | decompensation |
|----------------|----------------------------|------------------------|------------------------------------|--------------------------------|--------|----------------|
| 1              | 25                         | 23                     | 3.9cm                              | 3cm                            | -3.9cm | 2.5cm          |
| 2              | 40                         | 40                     | 5.7cm                              | 5.6cm                          | -4.3cm | 3.1cm          |
| 3              | 36                         | 32                     | 4.1cm                              | 3.2cm                          | 3.3cm  | 2.7cm          |
| 4              | 32                         | 30                     | 4.2cm                              | 3.8cm                          | 4.2cm  | 2.8cm          |

Table 2: Various Parameters



Graph 1: Comparison of Cobb's angle

It was seen that the Cobbs angle was reduced in 3 subjects while in one subject it was unchanged. Treatment with the Milwaukee brace for periods 6month lateral trunk shift, OBS, decompensation was reduced.

**V. DISCUSSION**

The Milwaukee brace has been the standard for orthotic management for scoliosis patients for decades. Several investigators have carried out biomechanically studies on the mechanism of action by which the milwaukee brace stabilizes scoliotic curves. The magnitude of forces generated by the orthosis have been measured experimentally.

Progression of the curve was found to be related to the pattern and magnitude of the curve; the age of the patient at the time of presentation; the Risser sign; and, in girls, the menarchal status. We recommend that immature adolescents who have a curve of more than 25 degrees and a Risser sign of 0 be managed with a brace immediately, rather than after progression has been documented.

The skeletal system is a close chain; therefore, the changes in one part can alter the normal balance of the other parts. The study suggests that careful adherence to mechanical principles in the use of a Milwaukee brace will result in successful treatment of more patients

**VI. CONCLUSION**

Though it is a high profile orthosis, patient acceptance is very less, still maxium correction is done by this orthosis. This brace provides the distraction force along the longitudinal axis of vertebral column ,hence the correction is maximum over the low profile spinal brace,because these braces provides horizontal force.Milwaukee brace provides effective correction of mild to moderate curve up to 40-45 degree during the growth period.Correction is more effective for high curves in comparison to other support. I.e- upper thoracic & cervical.

- **Conflict of Interest:** The authors declared no conflicts of interest with respect to the authorship and/or publication of this article.
- **Financial Disclosure:** No financial disclosure

**REFERENCES**



- [1.] Nachemson AL, Lonstein JE, Weinstein SL. Scoliosis Research Society; Denver: 1982. Report of the Prevalence and Natural History Committee of the Scoliosis Research Society. [[Google Scholar](#)]
- [2.] Weinstein SL, Ponseti IV. Curve progression in idiopathic scoliosis. *J Bone Joint Surg Am.* 1983;65:447–55. [[PubMed](#)] [[Google Scholar](#)]
- [3.] Lenke CL. *SRS Terminology committee and working group on spinal classification.* Revised Glossary of Terms. Scoliosis Research Society; Milwaukee, US: 2000. [[Google Scholar](#)]
- [4.] Lonstein JE, Carlson JM. The prediction of curve progression in untreated idiopathic scoliosis during growth. *J Bone Joint Surg Am.* 1984;66:1061Y1071.
- [5.] Bunnell WP. The natural history of idiopathic scoliosis before skeletal maturity. *Spine.* 1986;11:773Y776
- [6.] TP; Schultz, AB; Belytschko, TB; Dewald, R, Milwaukee brace correction of idiopathic scoliosis. A biomechanical analysis and a retrospective study, *The Journal of Bone & Joint Surgery: September 1976 - Volume 58 - Issue 6 - p 806-815*
- [7.] Guo J, Liu Z, Lv F, Zhu Z, Qian B, Zhang X, et al. Pelvic tilt and trunk inclination: new predictive factors in curve progression during the Milwaukee bracing for adolescent idiopathic scoliosis. *Eur Spine J.* 2012;21:2050–2058. [[PMC free article](#)] [[PubMed](#)] [[Google Scholar](#)]
- [8.] Avinash G. Patwardhan, PHD ,Thomas M. Gavin, CO ,Wilton H. Bunch, MD, PHD Victoria M. Dvonch, MD ,Ray Vanderby Jr., PHD ,Kevin P Meade, PHD ,Mark Sartori “Biomechanical Comparison of the Milwaukee Brace (CTLSO) and the TLSO for Treatment of Idiopathic scoliosis”,[JPO>1996 Vol. 8, Num. 4.](#)
- [9.] J. Martin Carlson, CPO , Guest Editorial: “Treatment of Adolescent Idiopathic Scoliosis”, [JPO>2007 Vol. 19, Num. 3>](#) pp. 64-66
- [10.] Mr Andrew J Mills CO, Idiopathic Scoliosis: “Etiopathogenesis and Dynamic Corrective Brace Treatment Principles”, [Journal of Proceedings>2006>Sheffield Children’s Hospital Sheffield, United Kingdom](#)
- [11.] “Clinical Biomechanics: Musculoskeletal Actions and Reactions”, R. C. Schafer, DC, PhD.
- [12.] Scoliosis Research Society Instrument 24, *Eur Spine J.* Jul 2006; 15(7): 1108–1117.
- [13.] Thomas M. Gavin, CO ETIOLOGY,” Points of Consensus: Idiopathic Scoliosis”,[JPO>2003 Vol. 15, Num. 4>](#) pp. 14-16
- [14.] Adam, Clayton J. PhD; Askin, Geoffrey N. FRACS; Percy, Mark J. PhD, “Gravity-Induced Torque and Intravertebral Rotation in Idiopathic Scoliosis”,15 january 2008-volume 33-issue-2
- [15.] Zach Harvey, BSc, CO Megan Chamis, BSc, CO ,Robert Lin, BSc, CPO , “The Impact of Lateral Pads versus Posterolateral Pads in the Management of Idiopathic Scoliosis”, [JPO>2002 Vol. 14, Num. 4>](#) pp. 165-169.