ISSN No:-2456-2165

Lobular Capillary Hemangioma: An Extremely Rare Entity in the Retromolar Region: Case Report

Dr. Jambukeshwar Kumar B., Dr. Shreya H.R., Dr. Srikar M.V., Dr. Vidya K.C., Dr. Akshay Thilak

Abstract:- A benign growth of blood vessels called a hemangioma appears in both childhood and maturity. Early infancy fast endothelial cell growth, followed by involution throughout time, identify them as malignancies. Hemangiomas can be classified as either capillary or cavernous. The capillary shape appears as a flat region made up of lots of tiny capillaries. Large dilated sinuses filled with blood make up a cavernous hemangioma, which presents as an elevated lesion of vascular plexuses with a deep red color. They primarily affect white people more than people of color, are three times more common in women than men, affect the mandible more than the maxilla in a 2:1 ratio, and only five percent of intramuscular hemangiomas include the masseter muscle. This case of a patient with a lobular capillary hemangioma is being described to highlight the condition's uncommon occurrence and effective therapy.

I. INTRODUCTION

Patient MANJULA A. S., a 26-year-old woman with a growth in the right lower back tooth region for 15 days, came to our department of oral and maxillofacial surgery at the Coorg Institute of Dental Sciences in Virajpet with this complaint. The growth, which progressively grew in size, was first observed 15 days ago. Additionally, the patient had a history of bleeding and chewing problems. Patient lacked any pertinent medical background. On intraoral examination, a retromolar of tooth number 48 facing the lingual side displayed a 1.5x1.5 cm single, pedunculated, reddish pink swelling with smooth surface and impingement of opposing 3rd molar tooth. The lesion's surface seems ulcerated and white. (FIGURE 5A)

All the inspectory results were verified upon palpation. The lesion was firm in consistency, quickly bleeds when prodded, and was painful. On the digital pressure, compressibility and refilling of the lesion were visible. Because the patient had a history of chewing betelnuts, pan quid, and slaked lime 2-3 times per day during the previous six months, the patient had poor oral hygiene and stains. The radiograph (OPG) showed that there were 48 impacted and 18 buccal eruptions (FIGURE 4). A preliminary diagnosis of pyogenic granuloma was made based on the clinical presentation of the lesion. Capillary hemangioma, peripheral giant cell granuloma, and peripheral ossifying fibroma were among the differential diagnoses. A biopsy was planned for the same as an additional procedure. Oral prophylaxis and patient education about maintaining good oral hygiene and quitting the habit were performed after the patient provided informed consent. The results of the preoperative blood tests were all within normal limits. After a week, the patient was treated under aseptic conditions, and the growth and surrounding tissue were excised using electrocautery while the patient was under local anesthetic (1:80,000). Complete hemostasis was attained and bleeding was completely stopped by applying pressure with a gauze. Instructions and postoperative care were provided. For a standard histological study, the removed tissue was sent in a formalin bottle (FIGURE 2 AND FIGURE 3). After a week, the patient was brought back in, and the biopsy site healing went smoothly and satisfactorily.(FIGURE 5B) Additionally, the patient received recommendations for surgically extracting 48 and 18 teeth.

II. HISTOPATHOLOGICAL REPORT:

revealed discontinuous stratified squamous para-keratinized epithelium of variable thickness overlying a vascular, fibro cellular stroma associated with proteolytic changes, pseudo - dysplasia and epithelial proliferation. underlying connective tissue shows lobules of budding capillaries separated by setae, with focal collections of plasma cells along with Russel bodies. Telangiectatic and congested capillaries are appreciated throughout the connective tissue (feeder vessel) – final diagnosis of LOBULAR CAPILLARY HEMANGIOMA. (FIGURES 6)

III. DISCUSSION

Hemangiomas, which can be categorized as capillary or cavernous, are benign vascular tumors that are rather frequent. Although capillary hemangiomas are a common soft tissue tumor of the head and neck, they are very uncommon in the oral cavity. A rapid growth phase is followed by a slow involution in capillary hemangiomas, which are made up of numerous tiny capillaries lined with endothelial cells and sustained in the connective tissue stroma. The common soft tissue tumor of the oral cavity is called pyogenic granuloma. The doctor typically faces clinical confusion and difficulty in diagnosing these two lesions. Hemangiomas are benign tumors that are more common in children (7%) than adults[1]. Capillary hemangiomas are exceedingly uncommon intraorally, occurring in 0.5%–1.0% of all other lesions with a female preference (ratio of 3:1). Nayouki Matsumoto et al. examined 31 capillary hemangioma patients and discovered that the majority of lesions were identified in the buccal mucosa (45.2%), tongue (35.5%), lip (9.7%%), gingiva (6.5%), and palate (3.2 percent).[2]

Hemangiomas of the oral soft tissues can range in size from a few millimeters to several centimeters and present as painless, soft, smooth or lobulated, sessile or pedunculated lesions or growths. These lesions typically grow slowly and have a deep red or blue red tint when they first appear. These lesions frequently include adjacent teeth and the interdental papilla. They are typically painless[3]. Hemangiomas of the oral mucosa are managed differently

ISSN No:-2456-2165

depending on the patient's age, the size of the lesion, the region of involvement, and the clinical characteristics of the hemangioma. Surgery to remove the lesion, either with or without ligating the vessels and embolization, is the most popular form of treatment for hemangiomas. Other therapeutic approaches, including as steroid therapy, electrosurgery, laser surgery, cryosurgery, and the use of sclerosing agents, have recently also been developed. Surgery should be performed carefully, keeping in mind the potential for intraoperative and postoperative bleeding[4].

The lesion in this instance was less symptomatic and unpleasant. To rule out malignant conditions and check for the presence of any other foreign bodies that needed to be removed in addition to the lesion, radiographs were indicated. The therapeutic method in this instance was surgical excision. Hemangiomas often bleed profusely during surgical excision, however in this case, there was little to no bleeding, suggesting that the hemangioma may not be actively proliferating. The treatment had a positive effect on the patient[5].

IV. CONCLUSION

To understand the clinical behavior and potential dentoalveolar consequences of the capillary hemangioma, early diagnosis and biopsy are required. Capillary hemangioma is significant due to its associated vascular characteristics and consequences, despite the fact that it is a benign tumor of the oral cavity. Additionally, as the tissues may bleed heavily both before and after surgery, surgical care of hemangiomas should be done with prudence[6].

FIGURE – 1A LEFT PROFLE FIGURE – 1B FRONTAL PROFILE FIGURE 1C – RIGHT PROFILE

Fig. 1 - EXTRA ORAL PICTURES

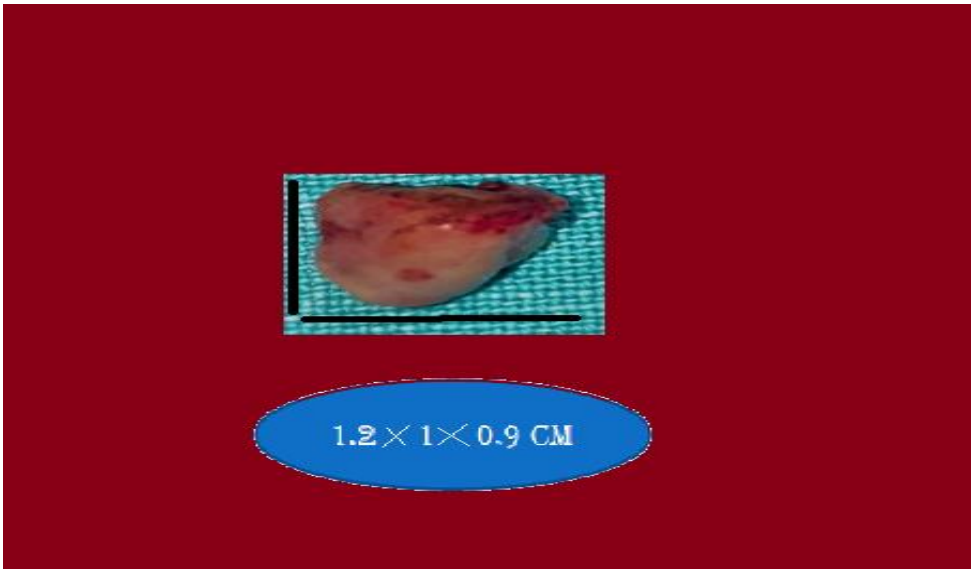

Fig. 2: EXCISIONED GROWTH MEASURING – 1.2*1*0.9 CM

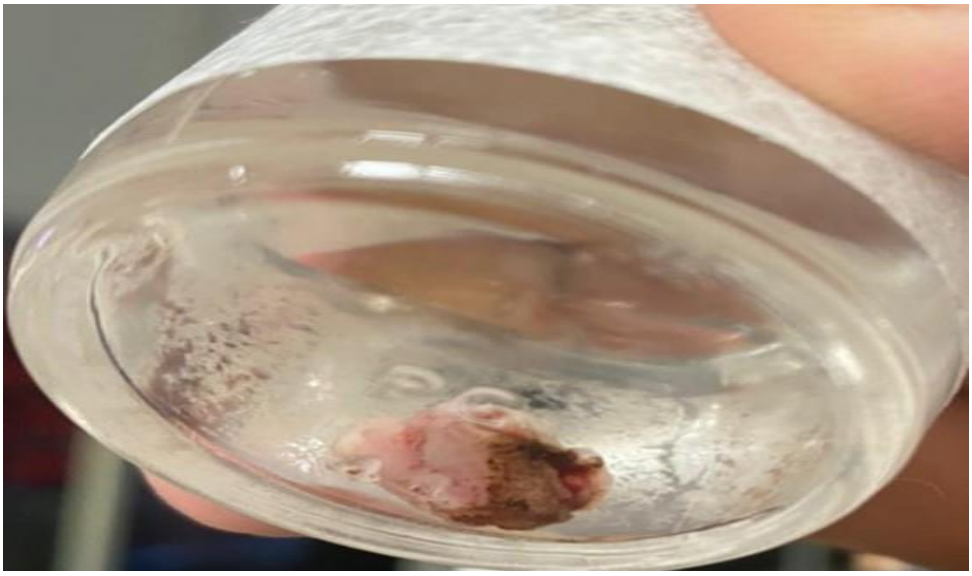

Fig. 3: SPECIMEN IN FORMALIN BOTTLE

Fig. 4: ORTHOPANTANOGRAM

ISSN No:-2456-2165

FIGURE 5A - PREOPERATIVELY

FIGURE 5B - POSTOPERATIVELY

Fig. 5: INTRA ORAL PICTURES

FIGURE 6A

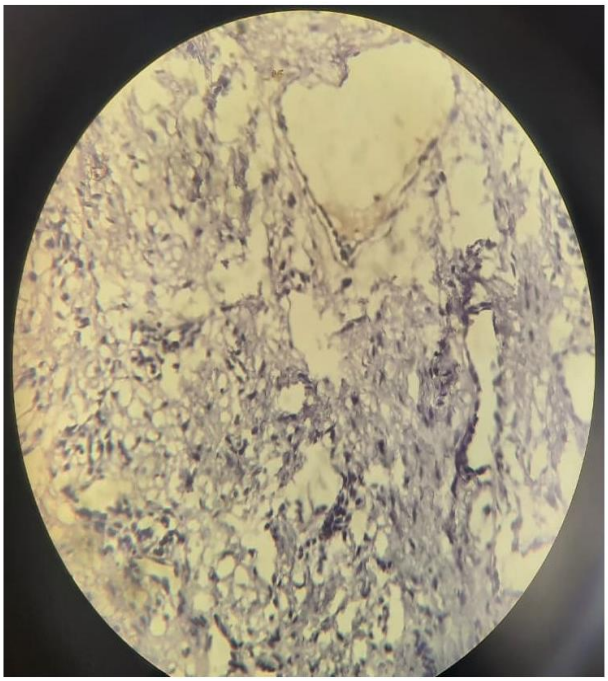

FIGURE 6 B

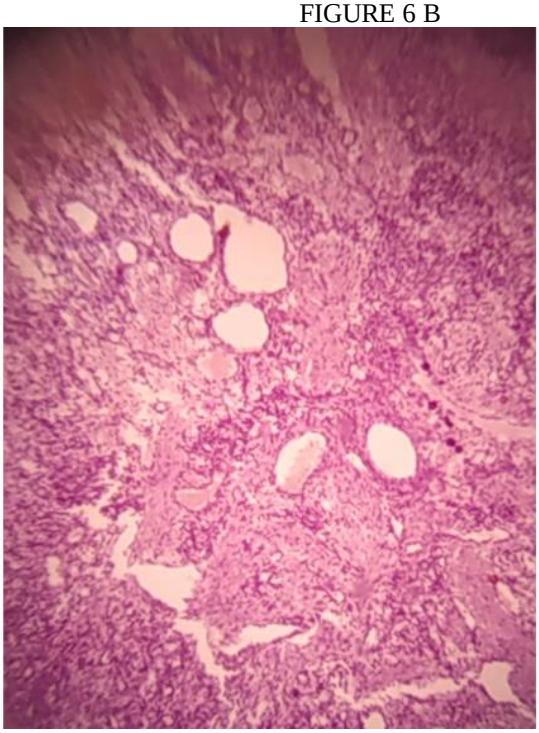

Fig. 6: HISTOPATHLOGICAL PICTURES

REFRENCES

[1.] Dilsiz A, Aydin T, Gursan N. Capillary hemangioma as a rare benign tumor of the oral cavity: a case report. Cases journal. 2009 Dec;2(1):1-6.
[2.] Kumari VR, Vallabhan CG, Geetha S, Nair MS, Jacob TV. Atypical presentation of capillary hemangioma in oral cavity-A case report. Journal of Clinical and Diagnostic Research: JCDR. 2015 Oct;9(10):ZD26.
[3.] Mills SE, Cooper PH, Fechner RE. Lobular capillary hemangioma: the underlying lesion of pyogenic granuloma. A study of 73 cases from the oral and nasal mucous membranes. The American journal of surgical pathology. 1980 Oct 1;4(5):470-9.
[4.] Lyssy LA, Puckett Y. Oral Hemangiomas. [Updated 2022 May 6]. In: StatPearls [Internet]. Treasure Island (FL): StatPearls Publishing; 2022 Jan-. Available from: https://www.ncbi.nlm.nih.gov/books/NBK560768/
[5.] Rachappa MM, Triveni MN. Capillary hemangioma or pyogenic granuloma: A diagnostic dilemma. Contemporary clinical dentistry. 2010 Apr;1(2):119.
[6.] Açikgözsurname A, Sakallioglu U, Özdamar S, Uysal A. Rare benign tumours of oral cavity–capillary haemangioma of palatal mucosa: a case report. International Journal of Paediatric Dentistry. 2000 Jun;10(2):161-5.