

Recurrent Bilateral Calcinosis of the Hip: A Case Report

Imane.Boujguenna (1), Fatima.Boukis (1), Hind.Ousehal (1), Fatiha.Benadra (1), Redouane.El Fizazi (2), Chihab.Bouyaali (3), Najat.Cherif idrissi gannouni (3), Anass.Fakhri (1), Hanane.Rais (1).

Department of pathological anatomy CHU MOHAMMED VI of MARRAKECH-MOROCCO
Department of pediatric orthopedic surgery CHU MOHAMMED VI of MARRAKECH-MOROCCO
Radiology Department CHU MOHAMMED VI of MARRAKECH-MOROCCO

Abstract :- Pseudo-tumor calcinosis is a rare benign tumor, characterized by a deposit of calcium material in the peri-articular soft tissues taking the appearance of a real tumor. We report the case of a 17-year-old adolescent boy with no specific history admitted for recurrent bilateral hip calcinosis.

Keywords:- Calcinosis, Recurrence, Pathological Anatomy, Hip.

I. INTRODUCTION

Pseudo-tumor calcinosis is a rare benign tumor, characterized by a deposit of calcium material in the peri-articular soft tissues taking the appearance of a real tumor. It comes in two clinical forms: the sporadic form, secondary to a chronic condition (chronic renal failure, hyperthyroidism, etc.) and the primary so-called familial form, probably of genetic origin.

II. MEDICAL OBSERVATION

We report the case of a young adolescent aged 17 years with no other personal or family history, followed for recurrent tumor calcinosis since the age of 3 years benefiting from repeated resection. Currently has 2 swellings in the 2 painful hips causing functional impotence. The clinical examination objectified the 2 swellings of the hip and the limitation of the extension of the ilio-femoral articulation. The patient benefited from a phospho-calcic assessment returning normal and a CT of a hip showing a bilateral multinodular circumscribed mass, requiring the carrying out of a surgical excision (Figure 1). The sample brought back was a calcified fibrous material whose histological study was in favor of numerous calcifications with granulomas with foreign body evoking a bilateral recurrence of pseudotumoral calcinosis (Figures 2,3).

III. DISCUSSION

Tumor calcinosis is a rare pathology, characterized by the development of calcified masses in the soft parts near the large joints [1], [2], [3], [4]. Just over 200 cases have been reported in the literature [2], [5]. The primary familial form is very rare with around 100 cases described [6].

The term tumor is improper, since there is no tumor tissue proliferation. This name is linked to the impressive size of the calcifications, to recurrences after surgical excision [7], [8], as well as to certain disturbing radiological aspects, with in particular the possibility of bone erosion with regard to the calcified masses [7].

Tumor calcinosis is encountered in two situations: the first is primary, initially called calcino-granulomatosis, is an unknown condition, of very probable genetic origin, linked to familial hyperphosphoremia of enzymatic origin [7], [8], [9]; without associated chronic renal failure [8]. Almost a third of patients have a similar family history [1]. There is a biological abnormality in the form of an isolated hyperphosphoremia, alkaline phosphatases and parathormone are normal [9].

The second situation is more frequent [7], [8], [9], [10] and is a relatively rare complication of renal failure (1 to 7% of cases) [11]. Little is known about the pathophysiology of people with kidney disease. Some authors discuss the role of increasing the serum Ca / P ratio, as well as phosphorus [9]. Secondary hyperparathyroidism is also implicated [9]. These two forms are identical on the clinical and radiological level [7], [8].

Tumor calcinosis is seen in adolescents and young adults [2]. Clinically, it presents as a swelling of variable size, of firm consistency adjacent to a large joint, it can be complicated by ulceration and infection.

The most common locations are the shoulder, elbows, buttocks, hands and knees. Compression of neighboring structures is possible [1], [7], [8], [9], [11].

Biology shows in most cases normal calcemia and elevated phosphoremia [2].

On the radiological level, the lesion sits in articular juxta [7], [11], producing a clustered appearance of opaque density of calcium deposits [1], [3], [7], [11].

The differential diagnosis arises with all the processes leading to calcium deposits in the soft parts, in particular: osteosarcoma, chondrosarcoma and gouty tophus.

Circumscribed ossifying myositis can be evoked but it is very rare.

The differential diagnosis also arises with dystrophic calcifications in venous insufficiency, parasitic infections, scleroderma and polymyositis; but the calcifications in these cases are often small and do not increase in size. It also arises with calcifications secondary to a pathology such as: hypervitaminosis D, chronic renal failure and secondary hyperparathyroidism [12]. But the clinical, biological and radiological signs point towards the diagnosis.

The pathological anatomy makes it possible to pose the diagnosis of certainty after biopsy or surgical resection showing at the macroscopic stage a multilobed mass formed of cubicles of variable size, and separated by fibrovascular membranes. The opening of the cavities gives rise to yellowish white liquid material, cloudy, thick, with a mastic appearance.

The histological aspect differs according to the phases which can coexist within the same lesion.

The first active or early phase: composed of multiple small and irregular cysts, bordered by mononuclear cells (histiocytes) and giant multinucleated cells containing granular debris. Cysts contain dense, grainy calcifications.

The second inactive or late phase: consisting of calcified material surrounded by fibrous tissue extending to adjacent structures with sometimes the formation of calcospherites. Croock and Silver believe that it is a collagen necrobiosis leading to the formation of cysts and a granulomatous reaction followed by calcification. McKee and Liomba even observed bone metaplasia.

The treatment of choice for tumor calcinosis is based on excision surgery in forms where the volume and / or localization are inconvenient [5], [9]. Treatment for the causative disease is initiated whenever possible. Some cases of spontaneous resolution have been reported in the literature.

IV. CONCLUSION

Tumor calcinosis is a rare entity, characterized by the deposition of calcium material in the periarticular soft tissues. The pathophysiology of this disease is still hypothetical.

It is a condition that can affect all age groups, with a predominance in young people in particular. The large joints are the seat of choice for the disease. Many other conditions responsible for calcifications of the soft parts must be ruled out before accepting the diagnosis of idiopathic tumor calcinosis.

It is on the confrontation of clinical signs, biology data and the imaging aspect that the disease is evoked. Confirmation is of course provided by the pathology examination. The treatment of idiopathic tumor calcinosis is

essentially surgical. Recurrences are frequent. The medical treatment remains incidental and of efficacy discussed. The prognosis for this condition is generally favorable. Finally, it should be noted that many gray areas still surround idiopathic tumor calcinosis. Advances in medical research could probably in the future pierce the different facets of this disease which remains mysterious.

Conflict of interest

The authors declare no conflict of interest.

Authors' responsibilities

Imane.Boujguenna and Fatima.Boukis: drafting of the manuscript

Fatiha Benadra, Anass Fakhri and Hanane Rais: correction of the manuscript

Redouane Elfizazi: clinical and surgical management of the patient

Chihab bouyaali and Najat Cherif Idrissi Gannouni: radiological follow-up of the patient

All authors contributed to the conduct of this work

ACKNOWLEDGMENT

To anyone who has participated in the care of this patient directly or indirectly

FIGURES

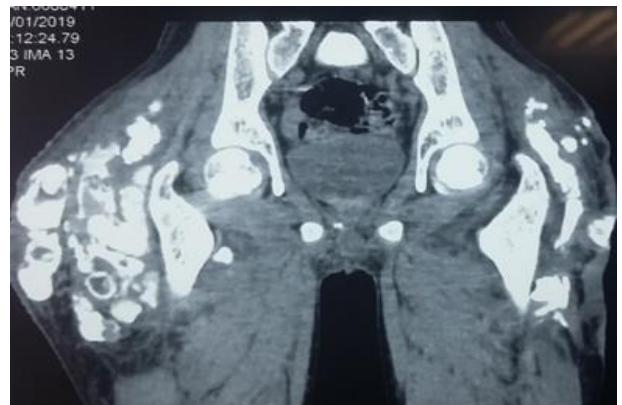


Figure 1: Computed tomography appearance of a circumscribed bilateral multinodular mass in favor of calcinosis of the hip

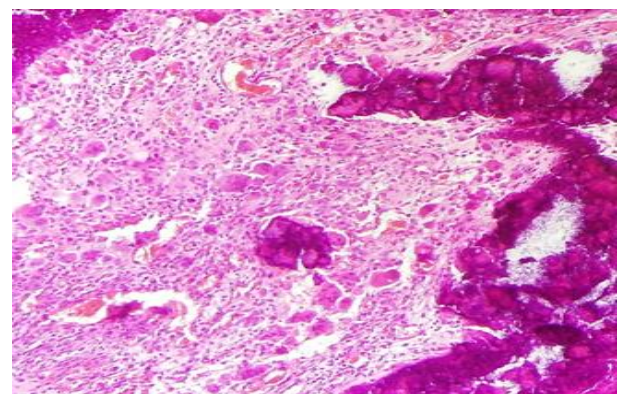


Figure 2: Microscopic appearance of numerous calcifications with foreign body granulomas suggesting pseudotumor calcinosis (x25)

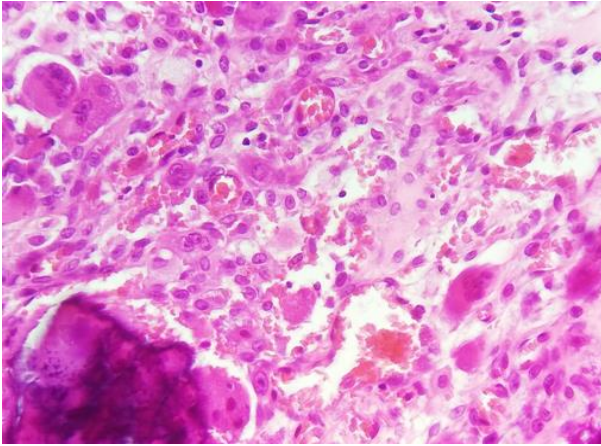


Figure 3: Microscopic appearance of numerous calcifications with foreign body granulomas suggesting pseudotumoral calcinosis (x40)

REFERENCES

- [1]. Abdoulaye Diallo Harouna, & Karima Atarraf, et Abderrahmane My Afifi. Calcinose pseudo-tumorale primitive chez l'enfant. *Pan Afr Med J.* 2017; 28: 239.
- [2]. Maiorano E. Hyperphosphatemic Familial Tumoral Calcinosis: odontostomatologic Management and Pathological Features. *Am J Case Rep.* 2014;15:569–75.
- [3]. Fikri M, Allali N, Dafiri R. La calcinose tumorale à propos de deux cas pédiatriques. *J Radiol.* 2007 Apr;88(4):595–8.
- [4]. Datta C, Bandyopadhyay D, Bhattacharyya S, Ghosh S. Tumoral calcinosis. *Indian J Dermatol Venereol Leprol.* 2005;71:293–4
- [5]. Bhat D, Parate S, Bobhate SK. Scrotal calcinosis presenting as nodular masses: A report of 4 cases. *Indian J Dermatol.* 2003;48:112–3.
- [6]. Prakash Hulivahana Muddegowda, Jyothi Basavanahalli Lingegowda, Ramkumar Kurpad Ramachandrarao, and Prasanna Guddappa Konapur. Calcinosis Cutis: Report of 4 Cases. *J Lab Physicians.* 2011 Jul-Dec; 3(2): 125–126.
- [7]. Ngo S, Vandhuick T, Janvresse A, Levesque H, Marie I. Des calcifications pseudotumorales. *Rev Médecine Interne.* 2011 Apr;32(4):251–2.
- [8]. Dubey S, Sharma R, Maheshwari V. Scrotal calcinosis: Idiopathic or dystrophic? *Dermatology.* 2010;16:5.
- [9]. Diniz RL, Javier RM, Durckel J, Dietemann JL. What is it? Pseudotumoral calcinosis. *J Radiol.* 1999 Jun;80(6):597–9.
- [10]. Maghraoui JE, Hammou M, Kabbali N, Arrayhani M, Houssaini TS. Amélioration de la calcinose tumorale de la main droite après para thyroïdectomie chez un hémodialysé chronique. *Pan Afr Med J.* 2016;24:30.
- [11]. Polykandriotis EP, Beutel FK, Horch RE, Grünert J. A case of familial tumoral calcinosis in a neonate and review of the literature. *Arch Orthop Trauma Surg.* 2004 Oct;124(8):563–7.
- [12]. Jellouli M, Gargah T. Tumoral calcinosis in a patient on hemodialysis. *Pan Afr Med J.* 2016;23:155.